
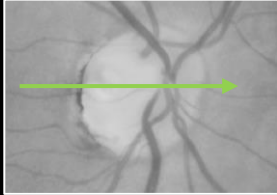
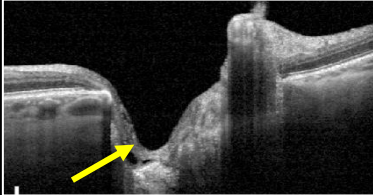
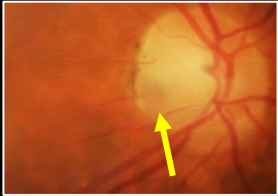
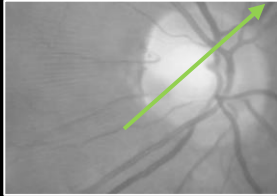

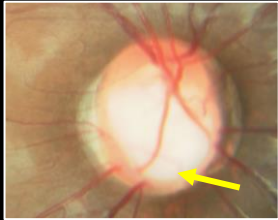
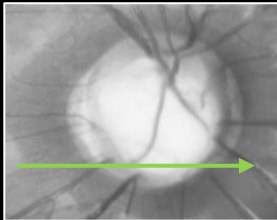
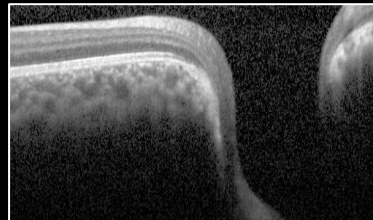
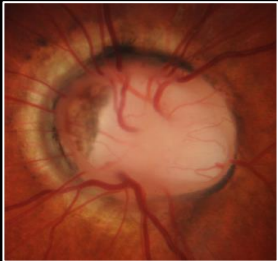
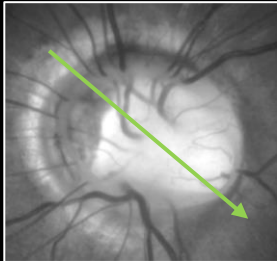
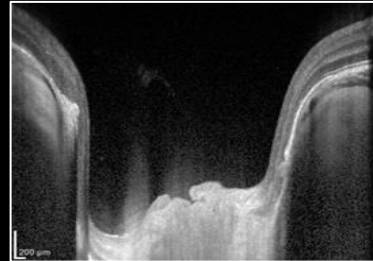



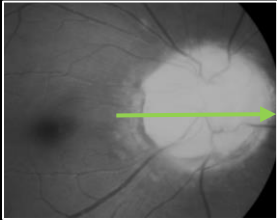
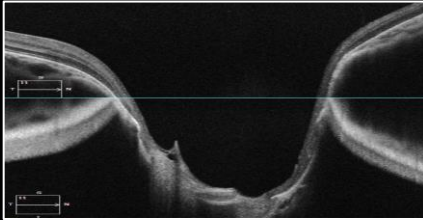

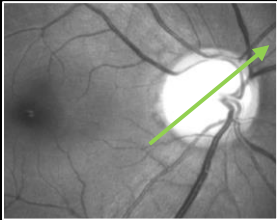
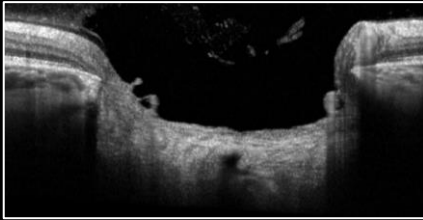
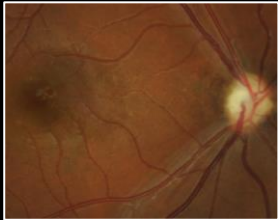
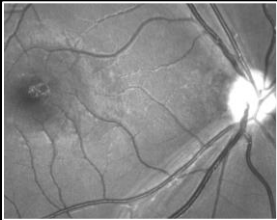



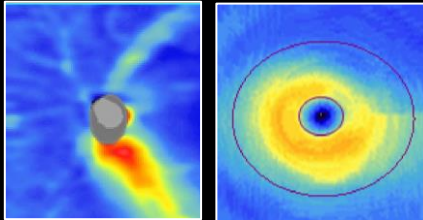
CONGENITAL STRUCTURAL DISC ANOMALIES

Retinal Photograph	Red-Free Image	OCT	Description
Congenital Optic Disc Pit (ODP)   			<ul style="list-style-type: none"> • Pathogenesis: Incomplete closure of the embryonic fissure during development . • Clinical appearance: Predominantly unilateral (85%), small hypopigmented greyish oval or round shaped excavation in the ONH of 1/8 to 1/4 ONH size; often located temporally or infero-temporally, but may occur at any location on the edge of disc or centrally (10-20%). • Complications: Associated with optic disc pit maculopathy (ODP-M) in 25-75% of cases. • OCT: <ul style="list-style-type: none"> • ODP: Small focal excavation in the ONH cup at the level of the lamina cribrosa. • ODP-M: Shows retinoschisis, intra-retinal fluid (either ONL, INL, GCL, sub-ILM) or serous macular detachment adjacent to an optic disc pit. • Visual fields: May have a paracentral arcuate defect, or other defects mimicking glaucoma. <p><i>ODP requires routine optometric review and patient education regarding risk of maculopathy. Baseline visual fields assessment should be considered if there are associated RNFL defects.</i></p> <p><i>ODP-M requires onward referral to an ophthalmologist for consideration of treatment.</i></p>
Congenital Optic Disc Pit Maculopathy (ODP-M)   			
Optic Nerve Coloboma   			
Morning Glory Syndrome   			

*Bilateral disc dysplasia/coloboma is associated with Papillorenal syndrome – an inherited condition affecting eye and kidney development which can result in renal failure. Disc dysplasia may be asymmetric between the eyes.

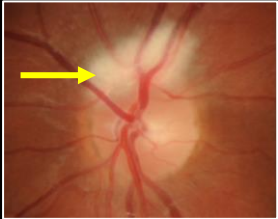

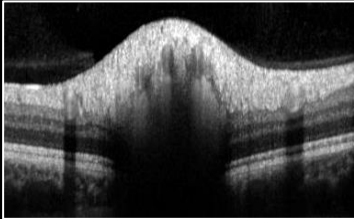

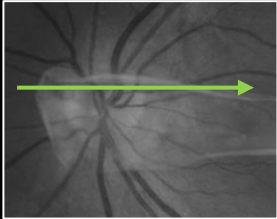
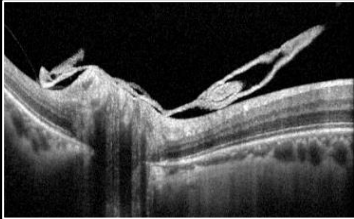
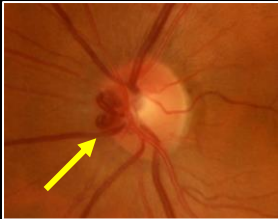
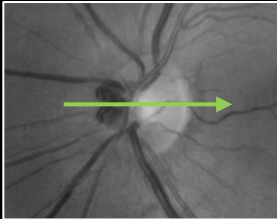
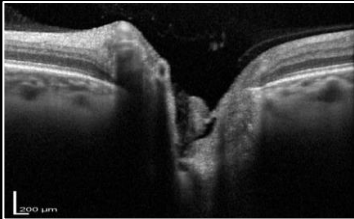


CHAIR-SIDE REFERENCE: OPTIC NERVE HEAD ANOMALIES

Retinal Photograph	Red-Free Image	OCT	Description
<p>Peripapillary Staphyloma</p> 			<ul style="list-style-type: none"> • Pathogenesis: Incomplete development of the posterior sclera. • Clinical appearance: Predominantly unilateral, staphyloma surrounding the ONH, with the ONH located at the base of the staphyloma. • OCT: Shows a deep posterior excavation around the ONH. • Visual fields: May show an enlarged blind spot. <p><i>Baseline glaucoma assessment followed by routine optometric review.</i></p>
<p>Megalopapillae</p> 			<ul style="list-style-type: none"> • Pathogenesis: Specific pathophysiology unknown. May be due to modified optic axonal migration in early embryogenesis in children with basal encephalocele. • Clinical appearance: Abnormally large ONH with a disc area $>2.5\text{mm}^2$, with an increased cup diameter with a deep excavation, yet intact rims and normal IOP. • OCT: RNFL and GC-IPL thicknesses within the normative range. • Visual fields: Normal, or may show an enlarged blind spot. <p><i>Baseline glaucoma assessment followed by routine optometric review.</i></p>
<p>Optic Nerve Hypoplasia</p> 		 <p style="text-align: center;"><i>GC-IPL thickness map RNFL thickness map</i></p>	<ul style="list-style-type: none"> • Pathogenesis: Underdevelopment of the optic nerve, resulting in a reduction in the number of axons in the affected nerve. • Clinical appearance: Mainly bilateral (75-85%), small pale/grey ONH. Yellow-white ring surrounds ONH ("double-ring sign"). Disc-mac distance to disc-diam. ratio >3.0 • OCT: Significantly reduced RNFL and GC-IPL thicknesses. • Visual fields: variable defects depending on distribution of the lack of nerve fibres. • Associations: May occur in isolation or with strabismus, microphthalmos, aniridia, coloboma, nystagmus, facial anomalies, septo-optic dysplasia with ONH, midline brain and endocrine abnormalities, etc. <p><i>Routine optometric review with visual fields assessment. Please note, evaluation with a paediatric ophthalmologist may be required if this is an initial diagnosis in a child.</i></p>
<p>Superior Segmental Optic Nerve Hypoplasia (Topless Disc Syndrome)</p> 		 <p style="text-align: center;"><i>RNFL thickness map GC-IPL thickness map</i></p>	<ul style="list-style-type: none"> • Pathogenesis: Specific pathophysiology unknown. May be due to Interruption in fetal development resulting in dysplasia of retinal neural tissue. • Clinical appearance: Relatively superior entrance of the central retinal artery from the ONH. Superior "double ring" sign, disc pallor, thinned superior peripapillary RNFL. • OCT: Abnormal extension of the RPE over the superior and nasal disc margin, significantly reduced superior RNFL and superior GC-IPL thicknesses. • Visual fields: Non-progressive, dense inferior visual field loss (sectoral or altitudinal), often connecting to the blind spot. • OCTA: Reduction in capillary perfusion corresponding to location of thinned RNFL • Associations: Possibly with maternal diabetes, low birth weight, short gestation time. <p><i>Routine optometric review with visual fields assessment.</i></p>

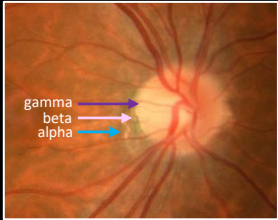
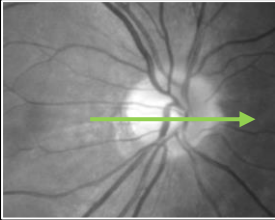
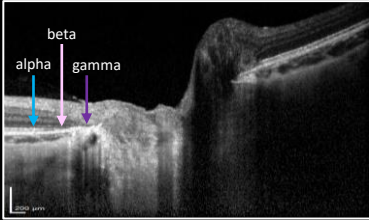

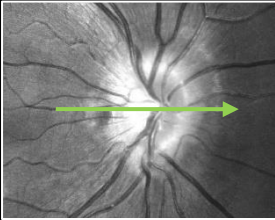
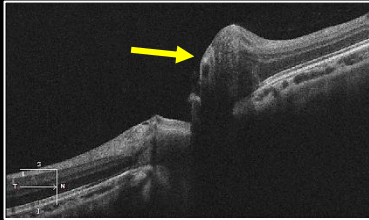

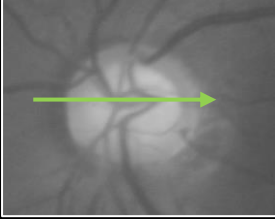
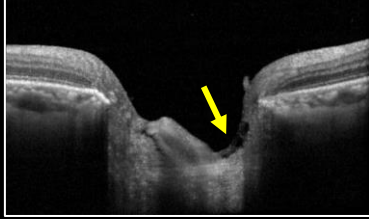
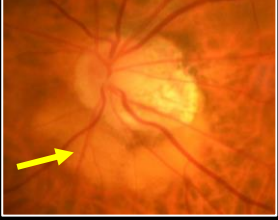
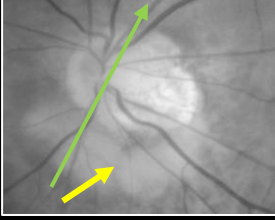
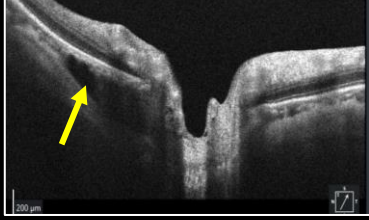
CHAIR-SIDE REFERENCE: OPTIC NERVE HEAD ANOMALIES

CONGENITAL ANOMALIES OF THE RNFL AND/OR VITREOUS

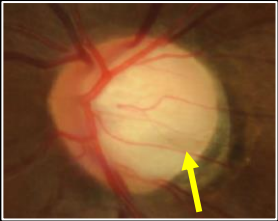
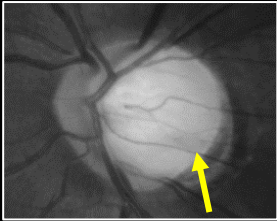
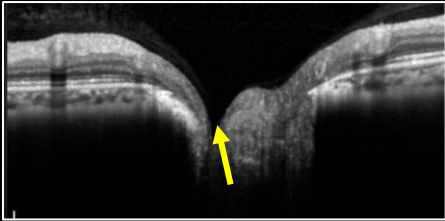
Retinal Photograph	Red-Free Image	OCT	Description
Myelinated Retinal Nerve Fibres (Medullated Retinal Nerve Fibres)			<ul style="list-style-type: none"> • Pathogenesis: Atypical continuation of the myelination surrounding the optic nerve fibres beyond the lamina cribrosa into the retina. • Clinical appearance: Grey-white patches following the curve of the RNFL with feathered edges which may obscure underlying retinal vessels. Often located in the peripapillary region but may also be present elsewhere in the retina. • OCT: Thickened RNFL in the location of the myelin. • Complications: Possible visual field defects depending on the location of the myelin. <p><i>Document and routine optometric review.</i></p>
			
Bergmeister Papilla			
			<ul style="list-style-type: none"> • Pathogenesis: Small glial tissue remnant at the ONH due to incomplete regression of the posterior hyaloid artery during development. • Clinical appearance: White-ish collection of glial tissue anterior to the ONH. • OCT: Hyper-reflective sheet of tissue located above the retinal plane and in the posterior vitreous space. • Associations: Often found in individuals born prematurely. <p><i>Document and routine optometric review.</i></p>
Pre-Papillary Vascular Loop			
			
			<ul style="list-style-type: none"> • Mostly asymptomatic and often requiring no intervention. • Typically arterial (>90%) and unilateral (83-91%). • Clinical appearance: Elevated and twisted vascular loop (arterial or venous) projecting from the ONH into the vitreous cavity and returning to the ONH. • Associations: May be rarely associated with branch retinal artery occlusion, transient monocular vision loss, sub-retinal haemorrhage, recurrent vitreous haemorrhage. <p><i>Document and routine optometric review.</i></p>



DISC ANOMALIES ASSOCIATED WITH MYOPIA

Retinal Photograph	Red-Free Image	OCT	Description
<p>Peripapillary Atrophy</p> 			<ul style="list-style-type: none"> • Enlargement of Gamma zone (parapapillary sclera with absence of the retinal pigment epithelium and Bruch's membrane) and Delta zone (area of gamma zone in which blood vessels of at least 50µm diameter are not present over a length of >300 µm) are both associated with axial length elongation. • Visual fields: May appear as an enlarged blind-spot which can increase in size over time. <p><i>Document and routine optometric review.</i></p>
<p>Myopic Tilted Disc</p> 			<ul style="list-style-type: none"> • Fundus appearance: Myopic fundus with oval-shaped, obliquely rotated ONH, typically towards the temporal direction. • OCT: Nasal border of the disc is elevated, as is the RNFL at the nasal disc edge. • Complications: Increased risk of developing RNFL defect due to compression of axons and alterations to axonal transport (tilted disc syndrome). <p><i>Annual optometric review required with baseline visual fields assessment. Consider referral to a neuro-ophthalmologist to exclude optic disc swelling.</i></p>
<p>Pre-Laminar Schisis</p> 			<ul style="list-style-type: none"> • OCT: Splitting of the superficial pre-laminar tissue at the optic disc. • Associations: Historically believed to be suggestive of glaucomatous damage, although recent studies show associations with pathological myopia, particularly when retinoschisis is also present. <p><i>Document and routine optometric review.</i></p>
<p>Peripapillary Intrachoroidal Cavitation</p> 			<ul style="list-style-type: none"> • Fundus appearance: Crescent shaped yellow-orange lesion typically located inferiorly to the ONH, and adjacent to an area of peripapillary myopic conus. • OCT: Appears as thickening of the peripapillary choroid in early stages and may progress to an intrachoroidal triangular hypo-reflective space in later stages. • Associations: May cause visual field defects. <p><i>Annual optometric review inclusive of visual fields assessment and dilated fundus examination given high myopia.</i></p>

CHAIR-SIDE REFERENCE: OPTIC NERVE HEAD ANOMALIES

Retinal Photograph	Red-Free Image	OCT	Description
Acquired Optic Disc Pit   			<ul style="list-style-type: none"> • Clinical appearance: Subtle grey, oval-shaped depression along the outer border of the ONH or within the adjacent scleral crescent, typically at the superior or inferior pole of the ONH in myopic cases or centrally in glaucoma cases, the pit is often less well circumscribed compared to congenital cases. • Associations: glaucoma progression (higher rate of RNFL thinning), high myopia (long axial length). <p><i>Closer review period for glaucomatous eyes given higher risk of disease progression. Baseline glaucoma assessment and annual optometric review for high myopia cases.</i></p>

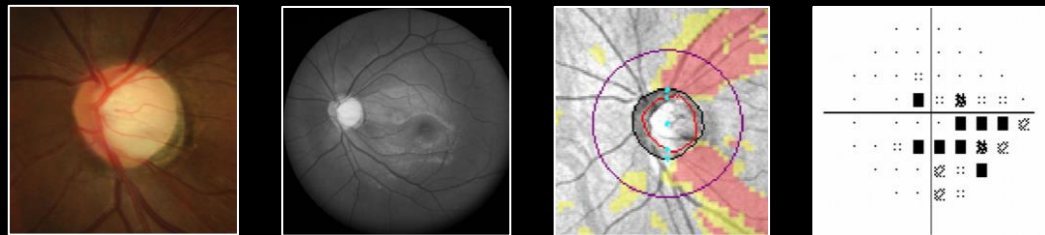
OPTIC ATROPHY

Optic atrophy is a term used to describe damage or degeneration of the retinal ganglion cell axons which results in a pale or grey-white optic nerve appearance or cupping indicating loss of neural tissue. The edges of the disc also lose the "soft" appearance seen in a healthy nerve and become much more distinct.

Causes of optic atrophy include:

1. **Primary optic atrophy:** Occurs without preceding optic disc swelling. Causes include toxic/nutritional, compressive or hereditary causes and retrobulbar optic neuritis.
2. **Secondary optic atrophy:** Refers to damage to retinal axons following an event of optic disc swelling. Common causes include papilloedema, optic neuritis and anterior ischaemic optic neuropathy (refer to "Optic Disc Elevation" reference).
3. **Retrograde degeneration:** Cortical lesions resulting in damage to the anatomically linked retinal nerve fibres, leading to sectoral or diffuse disc pallor with RNFL and ganglion cell thinning. Cupping of the disc can also occur in longstanding cases (refer to "Visual Fields" reference in this series).
4. **Consecutive optic atrophy:** Associated with diseases that affect the retina or its blood supply. This form of atrophy extends from a retinal cause through the axonal tissue towards the optic nerve. Underlying causes may include retinitis pigmentosa, vasculitis, retinal necrosis, retinitis or previous retinal photocoagulation.
5. **Glaucoma:** A progressive optic neuropathy. The key clinical features of glaucoma are characteristic changes to the optic nerve head and retinal nerve fibre layer, concordant visual field defects and progression over time (example below). Many of the causes of optic atrophy listed above may mimic glaucoma making it a diagnosis of exclusion.

GLAUCOMA



Glaucoma is characterised by:

1. Changes to the optic disc (A) including focal or global thinning of the neuroretinal rim and increased cupping.
2. Thinning of the RNFL, seen on red-free images (B), and flagged on the RNFL deviation map (C) on OCT.
3. Characteristic visual field defects that are concordant with identified RNFL thinning (D). The reference "visual fields" in this series explores glaucomatous field changes in more depth.

A NOTE ON MYOPIA AND GLAUCOMA

Myopia and myopic disc configuration resulting from long axial lengths can be associated with weakening of the optic nerve head tissues with instability particularly at the lamina cribrosa, leading to increased susceptibility to insult in glaucoma. Myopia and myopic disc configuration can also confound interpretation of the optic nerve and visual field result, mimicking glaucoma. Longitudinal data can assist in distinguishing myopic optic neuropathy from progressive and treatable glaucoma.