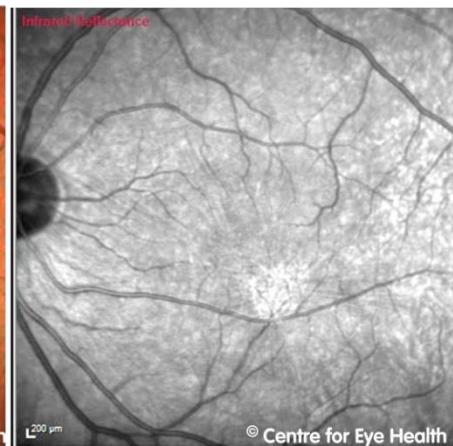
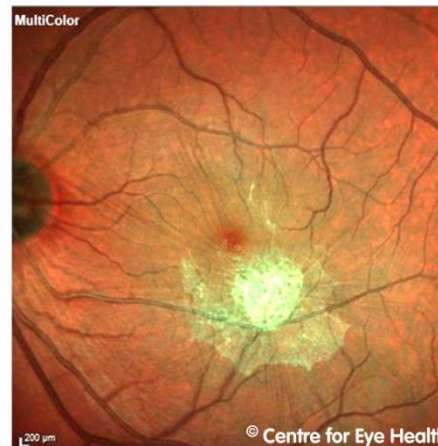
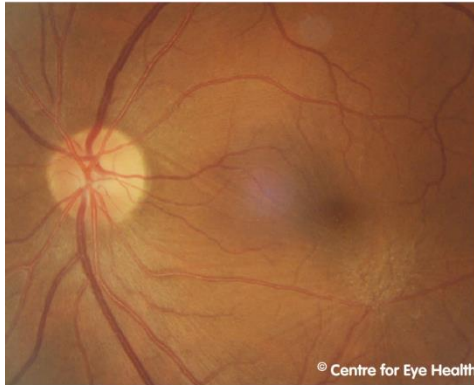
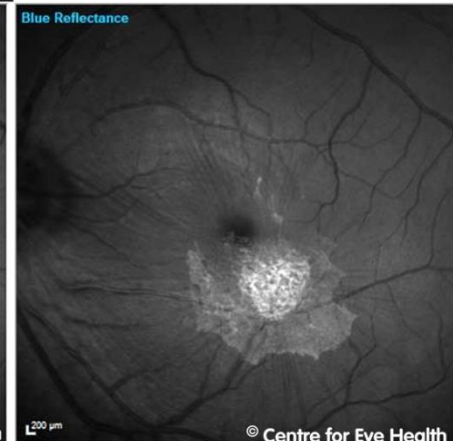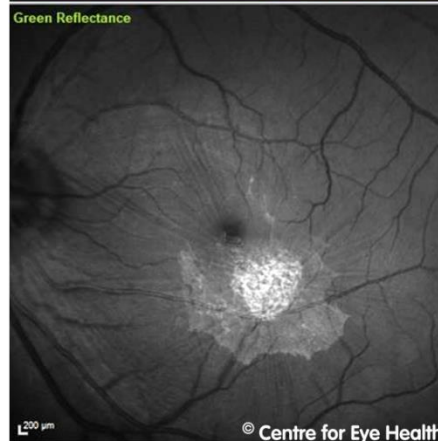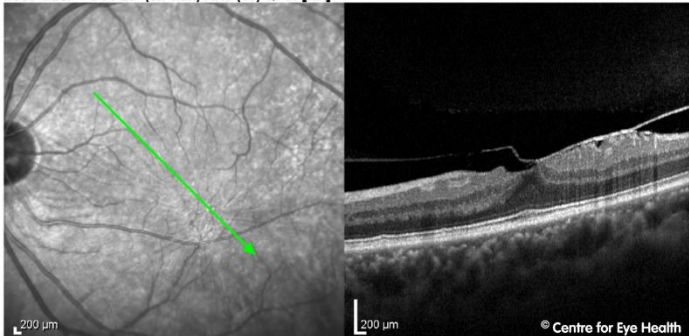


## CFEH Facebook Case #144

A 65 year old Asian male was referred to the Centre for a macula assessment due to an epiretinal membrane at his left macula. This case was interesting because it demonstrates the utility of multi-modal imaging in the examination of ocular pathology (retinal photos, red-free photo, Spectralis – multicolour, infrared reflectance, green reflectance, blue reflectance and OCT). Click on the link below to find out more about the different enface imaging modalities used in this case.



IR 30° ART + OCT 20° (5.7 mm) ART (19) Q: 41 [HR]



# Answer

The Spectralis HRA2+OCT has several different imaging modalities that can be used to highlight different pathologies.

1. Multicolour imaging: generates a series of three images simultaneously using different laser wavelengths (blue, green, infrared), providing additional information on the appearance of distinct structures at different depths within the retina. This imaging modality can be used on patients with media opacities or nystagmus and may highlight pathologies not readily visible with a traditional retinal examination. A 2017 study by Graham et al, showed multicolour to be more sensitive than colour retinal photography for detecting signs of early AMD.
2. Infrared reflectance: uses a longer wavelength of light to illuminate the fundus. This has several advantages as it can more readily penetrate opaque media (eg due to cataract) and the RPE, thus revealing structures deep in the choroid. Clinical uses include assessing the macula for reticular pseudodrusen in age-related macular degeneration.
3. Blue reflectance: “red-free” imaging which is achieved through illumination of the retina with blue light. These images are particularly useful to highlight pathologies affecting the superficial retina including retinal folds, epiretinal membranes and the retinal nerve fibre layer defects.
4. Green reflectance: is achieved through retinal illumination with green light and is most useful for examining blood, blood vessels, and exudates