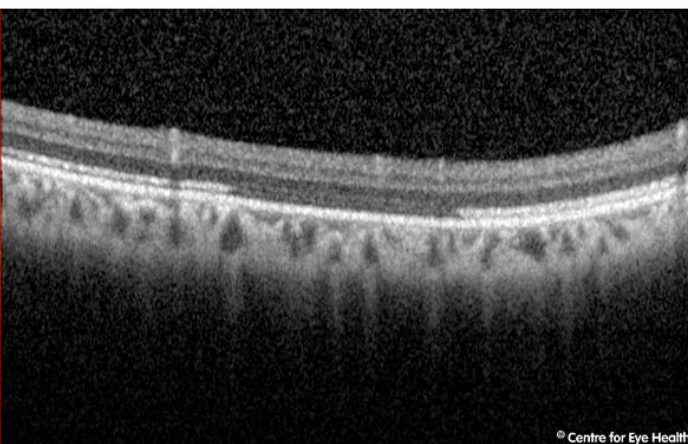
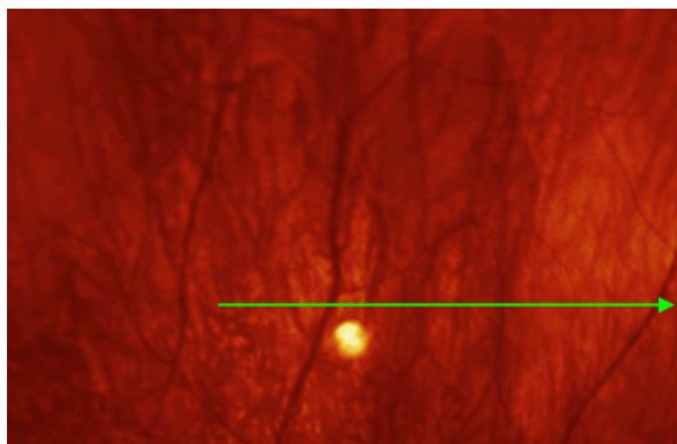
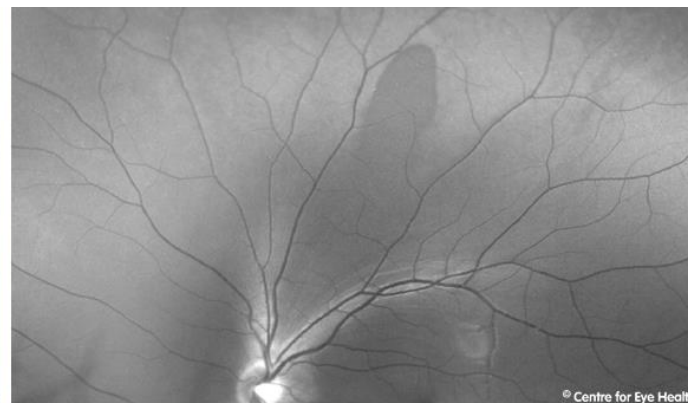
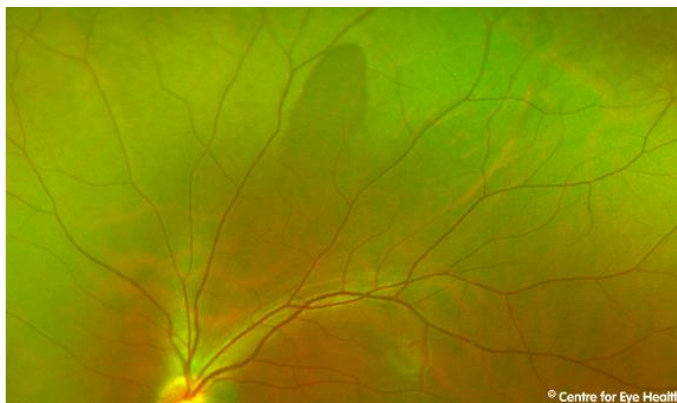




CFEH Facebook Case #81

A 28 year old Asian male presents for examination. He reports good general health, takes no medications and is asymptomatic. Can you identify the lesion seen superiorly in the left eye?



Proudly brought to you by

LEARNING FOR VISION



Centre for Eye Health



Optometry

NEW SOUTH WALES
AUSTRALIAN CAPITAL TERRITORY

ANSWER

It is an area of dark without pressure.

Dark without pressure refers to an area of darker retina with well-defined edges that are often scalloped. The OCT image through the lesion shows a change in the reflectivity of the ellipsoid zone in the area of the lesion. These lesions are benign but can change in appearance over time.

For a handy guide to differentially diagnosing peripheral retinal lesions, download the CFEH Chairside reference at:
https://centreforeyehealth.com.au/wp-content/uploads/2016/09/chairside_reference_peripheral-retina.pdf