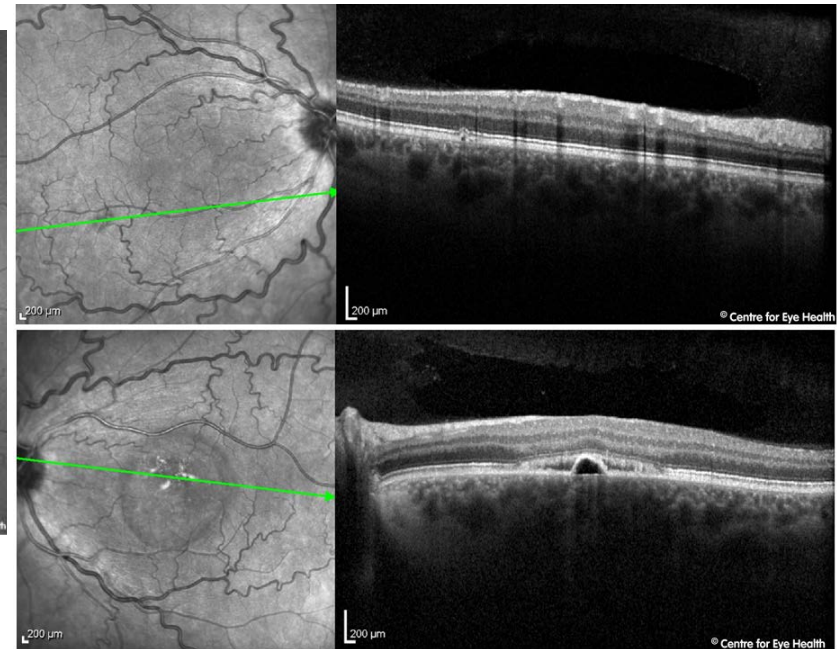
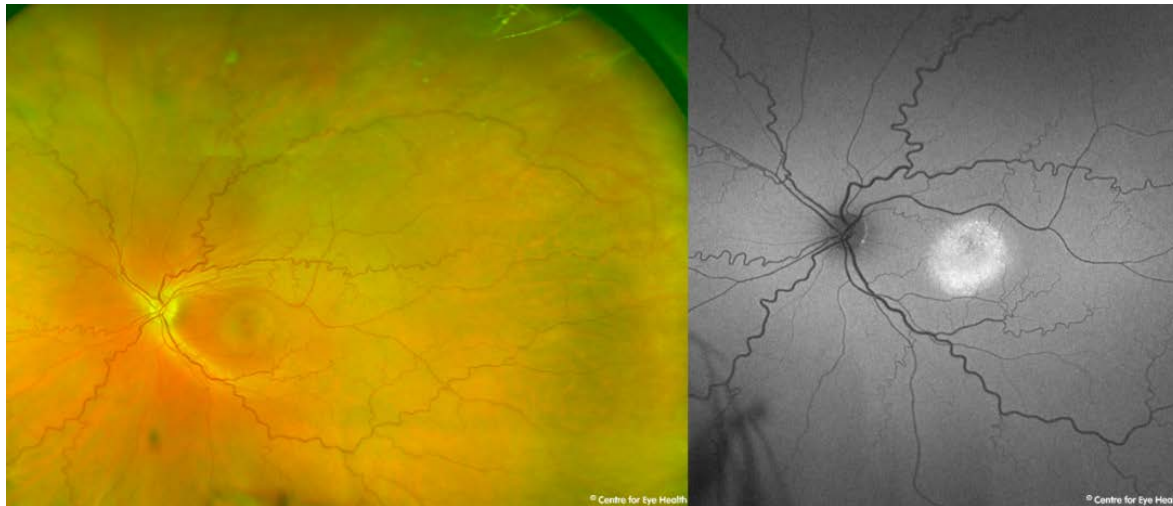



## CFEH Facebook Case #62

A 40 year old Caucasian male was referred to CFEH for a macular assessment. He is a smoker but reports good general health. Acuities were 6/6 RE and 6/9.5+ LE and amsler grid shows generalized distortion in the left eye only. His last eye examination was 6 years previous. From the images below, what is your management?



Proudly brought to you by

**LEARNING FOR VISION**



Centre for Eye Health



Optometry  
NEW SOUTH WALES  
AUSTRALIAN CAPITAL TERRITORY

# ANSWER

There are several pathological processes going on in this patient:

1. The marked tortuosity and dilated nature of the veins may indicate a pending central retinal vein occlusion
2. Pachychoroid spectrum disease. The large diameter of the hyper-autofluorescence indicates that this may be a chronic CSCR and the small serous PED surrounding subretinal fluid, indicates active disease.

Measuring the patient's blood pressure in-office found it to be 160/92. The retinal findings and elevated blood pressure measurements should be communicated to the patient's GP in a timely fashion with concurrent referral to an ophthalmologist.

For more information on hypertensive retinopathy, possible sequelae and management, please refer to CFEH's new chairside reference, released yesterday which covers all you need to know, click [here](#).

For further information on pachychoroid spectrum disease, refer to facebook case 55.