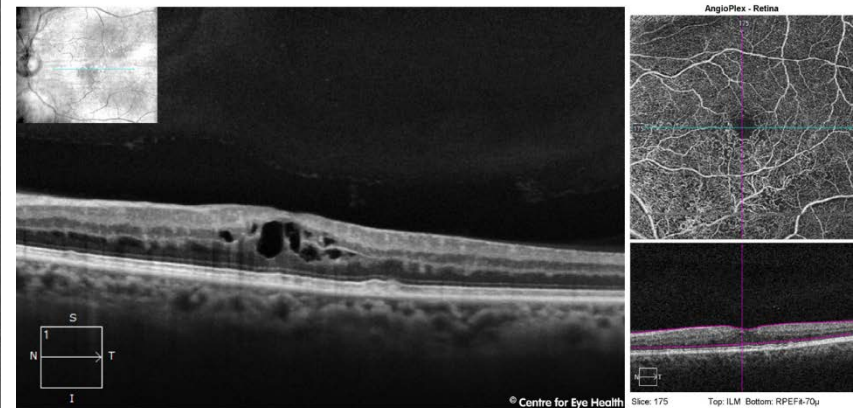
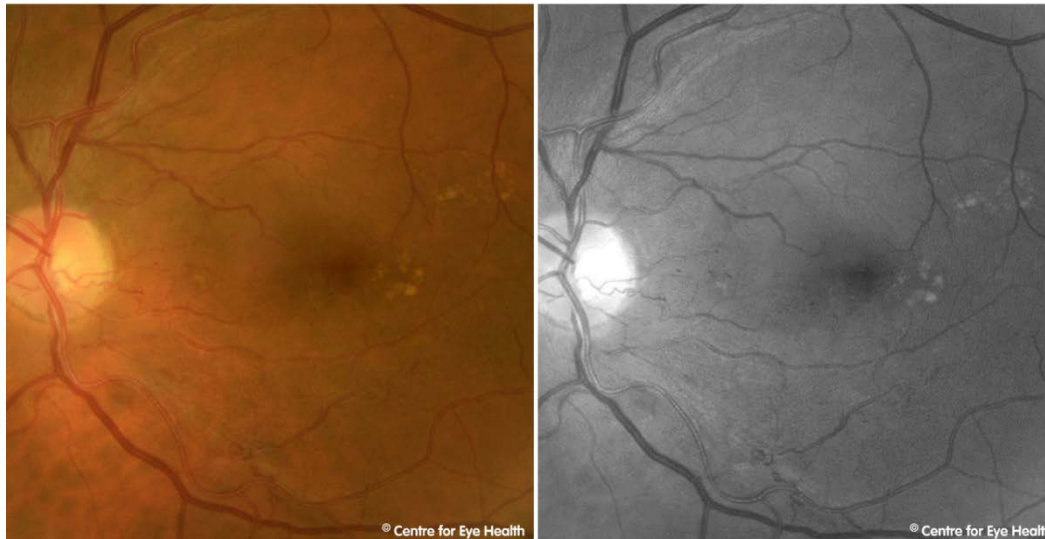



CFEH Facebook Case #111

A 60 year old Caucasian male presented for a macular assessment. He is a smoker and suffers from hypertension and gout for which he takes medications. The right eye was unremarkable so only the left will be discussed here. His corrected acuity in this eye is 6/9.5+. Can you identify the cause of the anomalous vasculature in this eye?



Proudly brought to you by

LEARNING FOR VISION



Centre for Eye Health



Optometry

NEW SOUTH WALES
AUSTRALIAN CAPITAL TERRITORY

ANSWER

Collateral vessels can be seen on the retinal photos infero-temporally. These can also be seen on OCTA. Resolving dot and flame haemorrhages and microaneurysms can be seen in the photos, and macular oedema is also present. These findings are consistent with a history of branch retinal vein occlusion. Additionally, there are medium sized drusen temporal to the macula.

This patient was referred to Ophthalmology for review.