



**CFE**



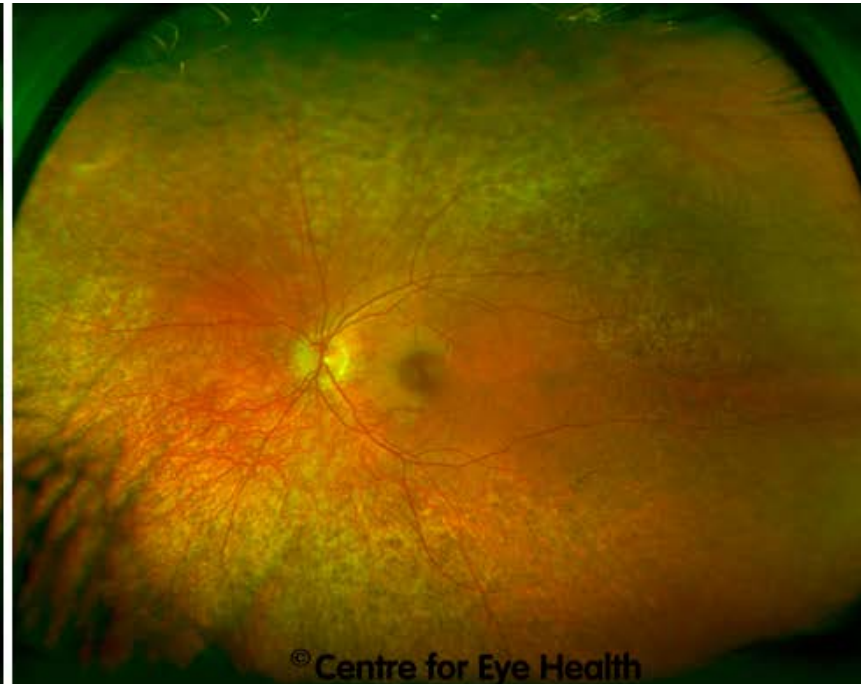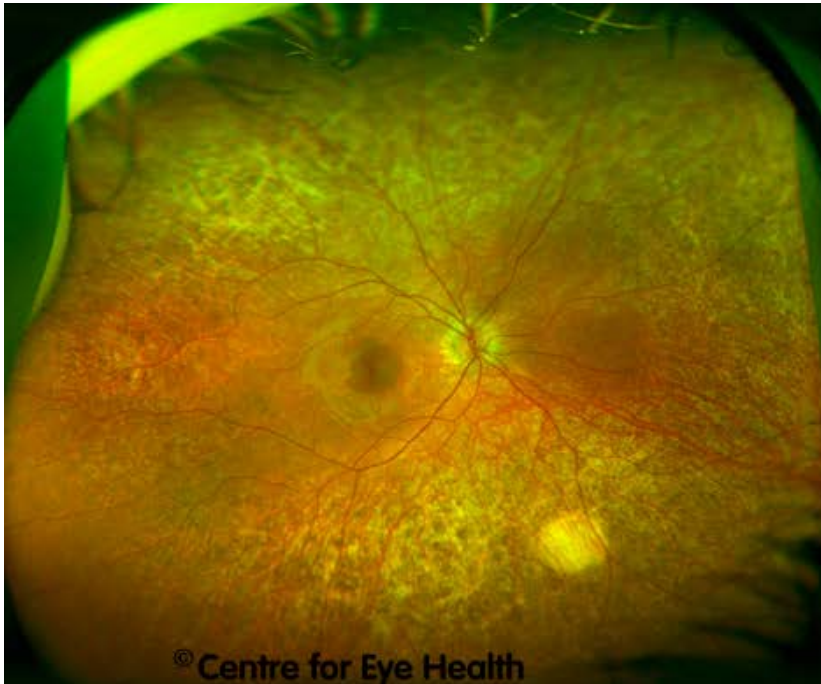
**Cases**

Centre for Eye Health

## CFEH Facebook Case #

An 8 year old boy was referred to CFEH for further examination regarding unusual retinal changes. His entering acuities were 6/6 in each eye and an Amsler grid revealed no distortion. His Optomap, fundus autofluorescence and visual field results for both eyes are included below. The OCT images taken of the right macula are also included. The left macula OCT results were similar to the right so have not been included.

**What is your diagnosis and what would be your management of this patient?**



Centre for Eye Health

The University of New South Wales  
Rupert Myers Building (south wing), Barker St, Gate 14  
Kensington NSW 2052

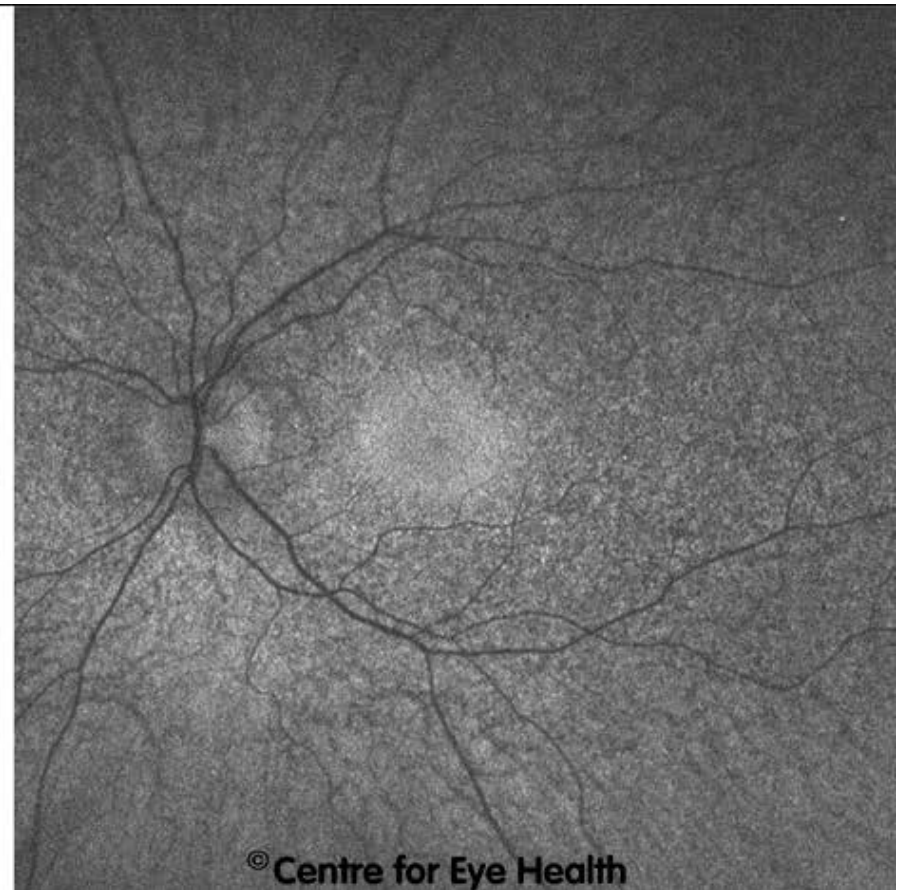
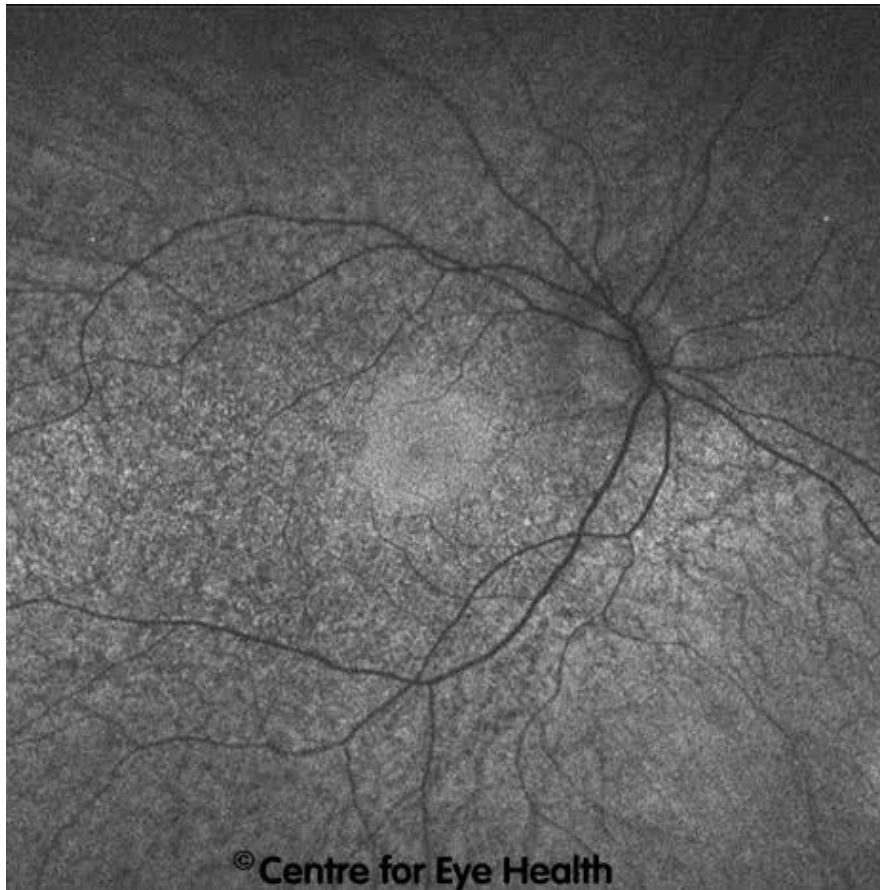
T. (02) 8115 0700 / 1300 421 960 F. (02) 8115 0799 E. [enquiries@cfeh.com.au](mailto:enquiries@cfeh.com.au) [cfeh.com.au](http://cfeh.com.au)

An initiative of Guide Dogs NSW/ACT and The University of New South Wales

ABN 85 132 812 143



Centre for Eye Health



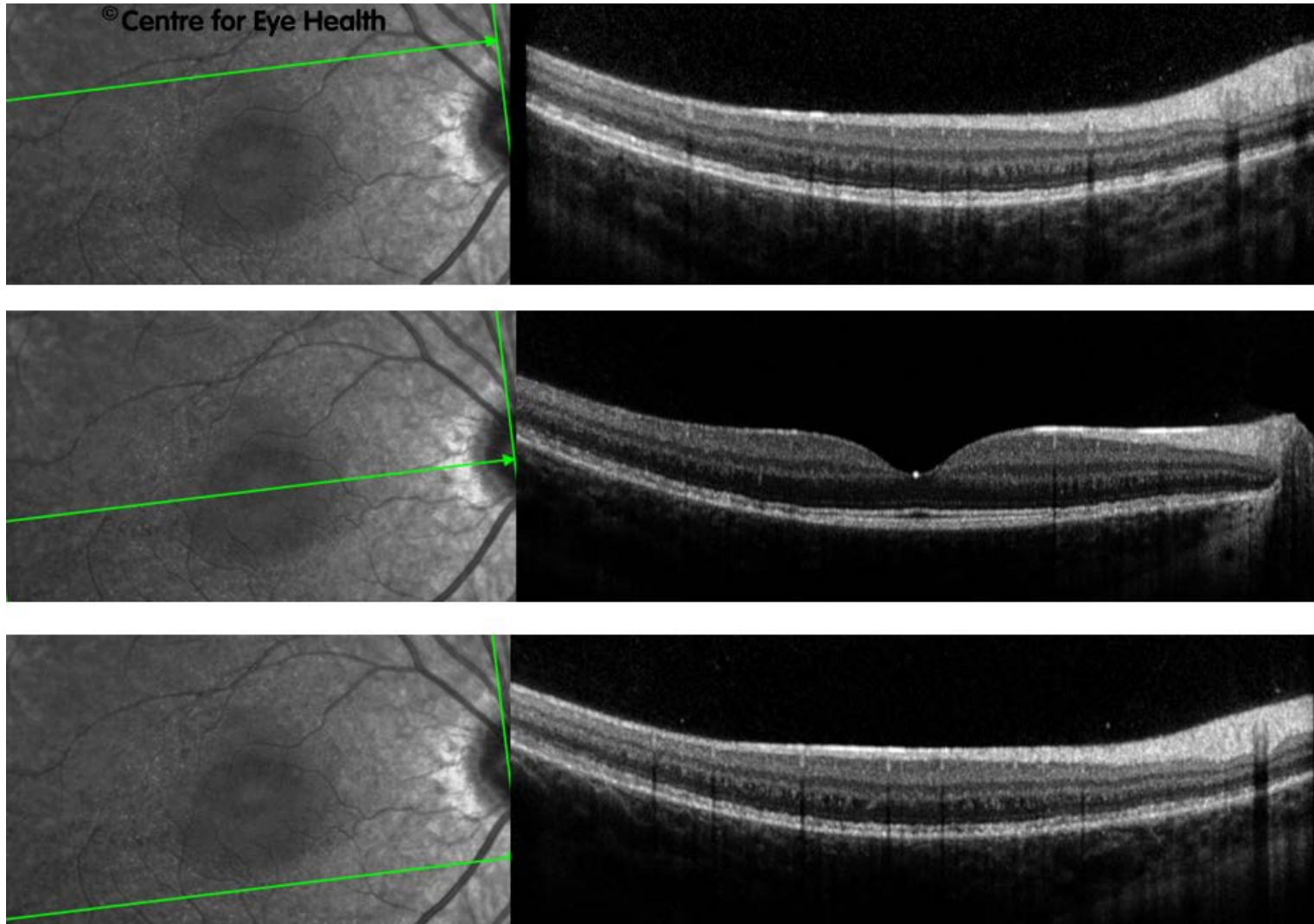
**Centre for Eye Health**

The University of New South Wales  
Rupert Myers Building (south wing), Barker St, Gate 14  
Kensington NSW 2052

**T.** (02) 8115 0700 / 1300 421 960 **F.** (02) 8115 0799 **E.** [enquiries@cfeh.com.au](mailto:enquiries@cfeh.com.au) [cfeh.com.au](http://cfeh.com.au)

*An initiative of Guide Dogs NSW/ACT and The University of New South Wales*

ABN 85 132 812 143



**Centre for Eye Health**

The University of New South Wales  
Rupert Myers Building (south wing), Barker St, Gate 14  
Kensington NSW 2052

**T.** (02) 8115 0700 / 1300 421 960 **F.** (02) 8115 0799 **E.** [enquiries@cfeh.com.au](mailto:enquiries@cfeh.com.au) [cfeh.com.au](http://cfeh.com.au)

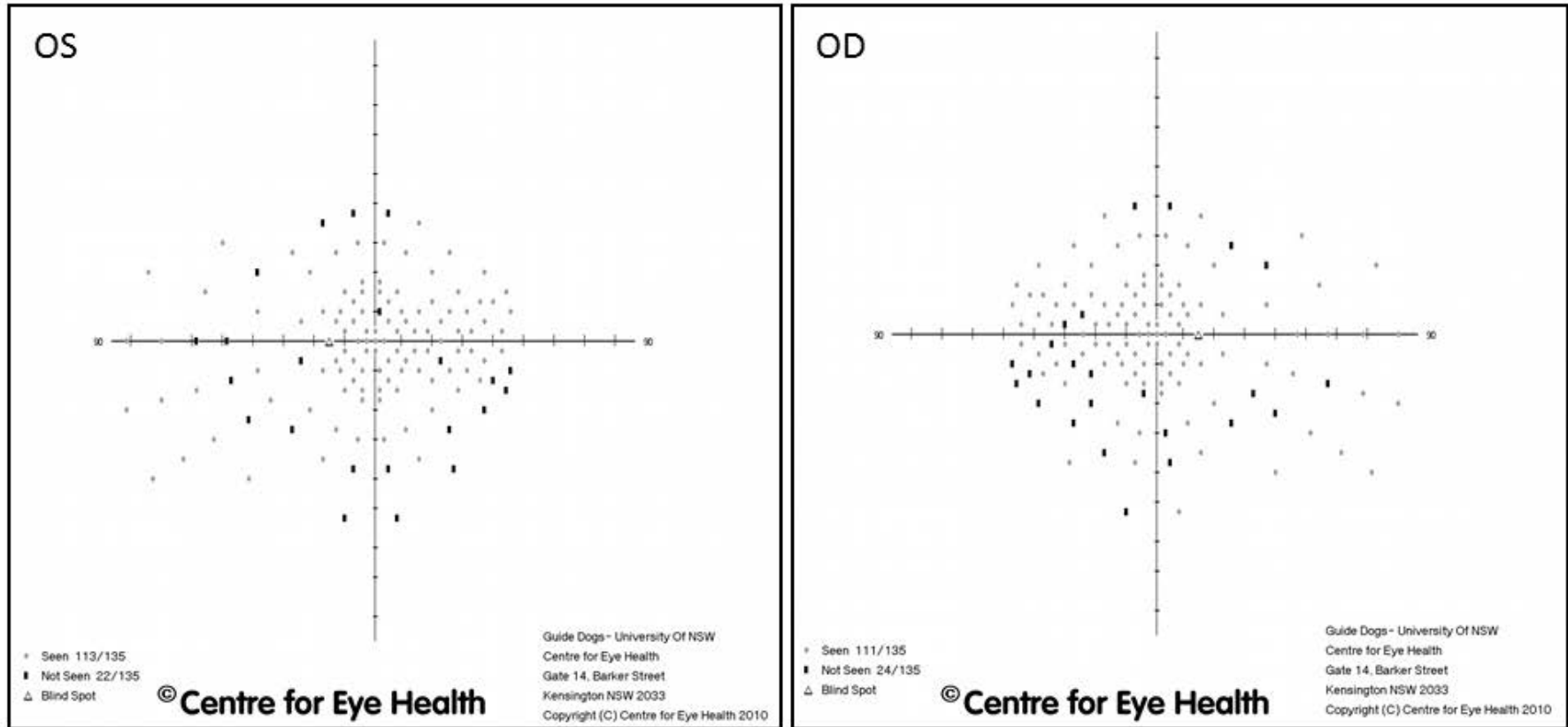
*An initiative of Guide Dogs NSW/ACT and The University of New South Wales*

ABN 85 132 812 143





HFA - 135 Point Screening Test



Proudly brought to you by

LEARNING FOR VISION

and



Centre for Eye Health

The University of New South Wales  
Rupert Myers Building (south wing), Barker St, Gate 14  
Kensington NSW 2052

T. (02) 8115 0700 / 1300 421 960 F. (02) 8115 0799 E. enquiries@cfeh.com.au cfeh.com.au

An initiative of Guide Dogs NSW/ACT and The University of New South Wales

ABN 85 132 812 143



# ANSWER

## Choroideraemia

**Choroideraemia is a progressive degeneration of the RPE and choriocapillaris. It has an X-linked recessive inheritance pattern and is thus found mostly in males.**

**Early in the disease process, the mid-peripheral photoreceptors are affected causing mottled areas of pigmentation as seen in this patient. Symptoms include problems with dark adaptation and night vision complaints. Presentation is usually in the first or second decade of life.**

**Over time the areas of mottled pigmentation and atrophy progress producing a ring scotoma similar to retinitis pigmentosa (RP). This condition is distinguished from RP however by the marked choroidal and RPE atrophy that develops, the fact that the blood vessels are unaffected and the absence of optic atrophy. Although the onset of symptoms in this condition is in early childhood, most sufferers have a slow course of degeneration and progression with most maintaining good vision for 40-50 years.**

**Looking at the imaging results from this patient, widespread choroidal and RPE atrophy can be seen in the midperipheral and peripheral fundus. There is associated pigment granularity in both eyes. The right eye shows an area of more advanced RPE and choroidal atrophy, seen on the inferonasal fundus. At this time there is a relative sparing of the central fundus in both eyes.**

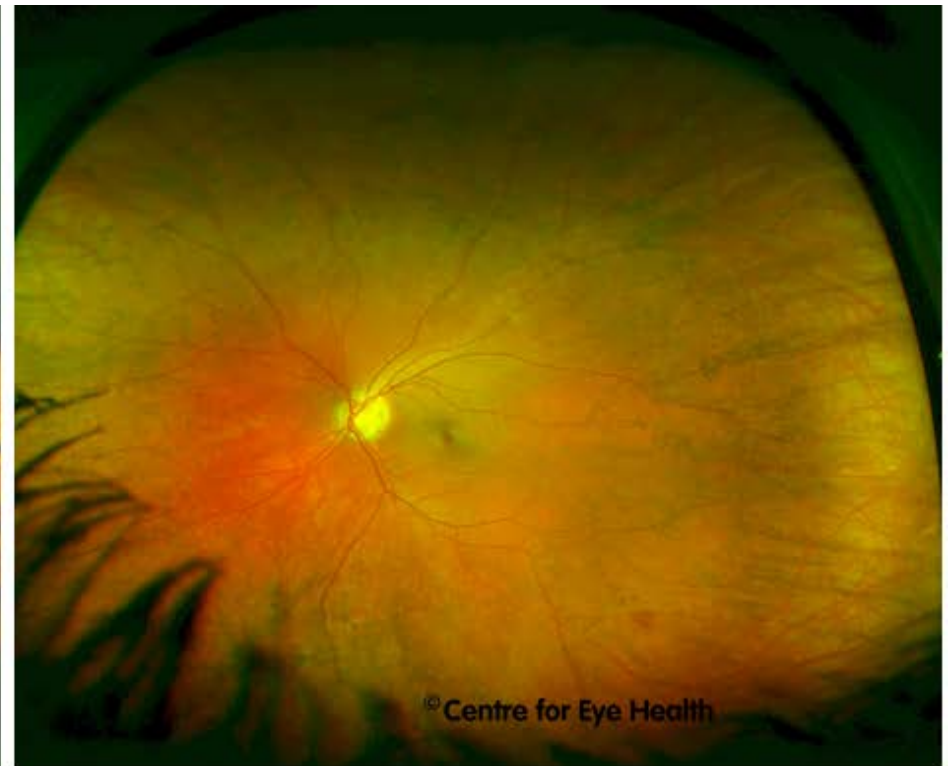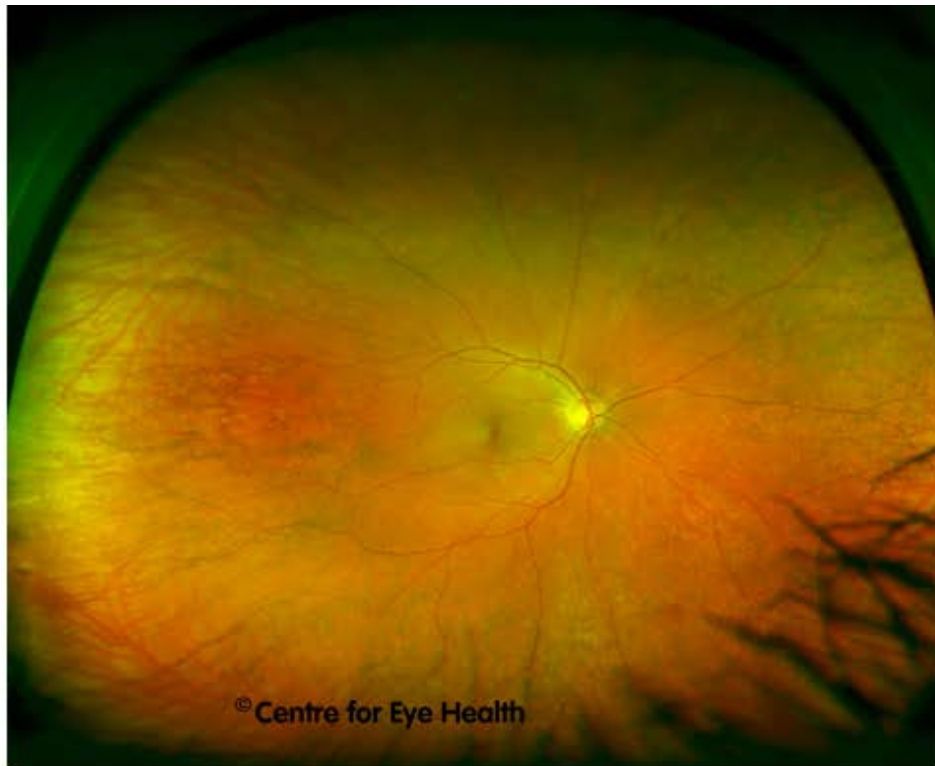**OCT line scans show widespread irregularity in the inner segment ellipsoid line, inner RPE and outer retinal layers in the top and bottom images. The scan through the fovea however shows the central macula region to be relatively unaffected at this time.**

**To confirm the diagnosis, electrophysiology testing was conducted at CFEH.**



## ANSWER

Carriers of X-linked choroideraemia often show patches of subretinal mottled pigment and occasionally a lobular pattern of choriocapillaris and RPE loss, but are asymptomatic and have normal electrophysiology results. For this reason, the patient's mother was also examined and her Optomap images follow on this and the next page:



**Centre for Eye Health**

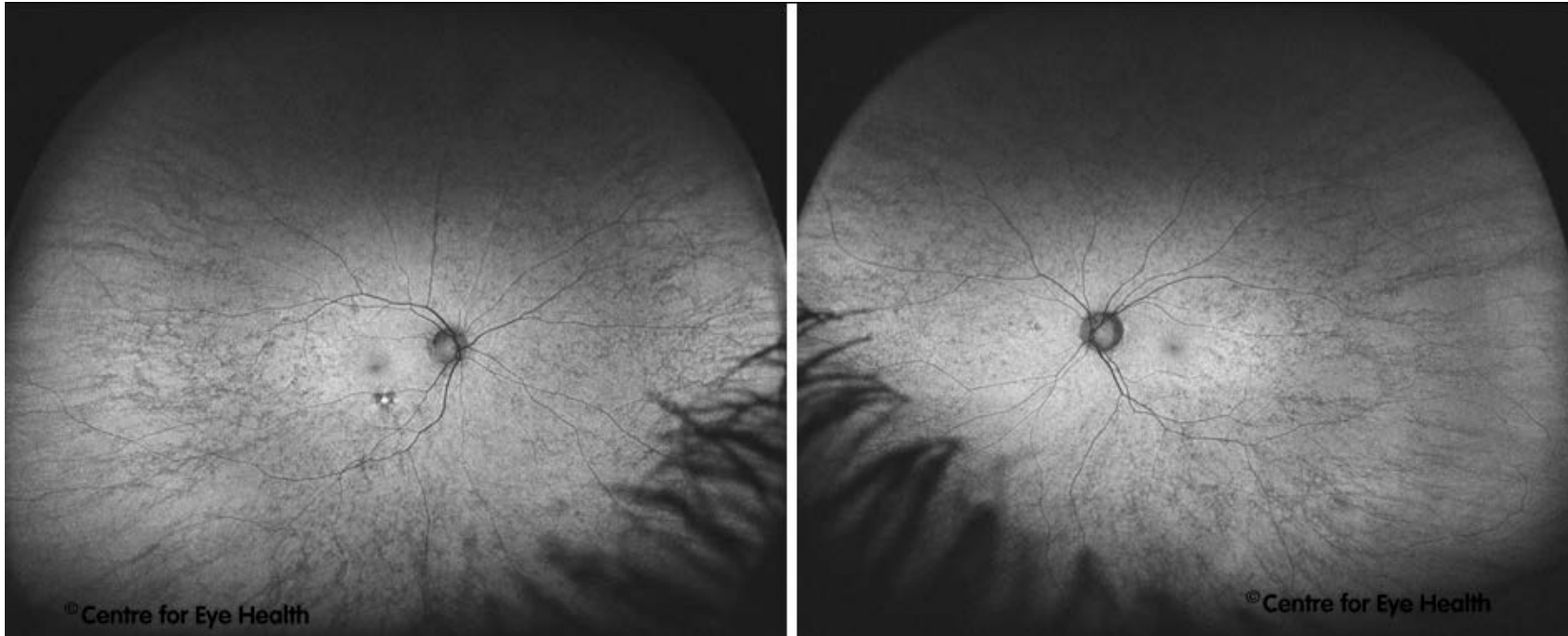
The University of New South Wales  
Rupert Myers Building (south wing), Barker St, Gate 14  
Kensington NSW 2052

T. (02) 8115 0700 / 1300 421 960 F. (02) 8115 0799 E. [enquiries@cfeh.com.au](mailto:enquiries@cfeh.com.au)  
[cfeh.com.au](http://cfeh.com.au)

An initiative of Guide Dogs NSW/ACT and The University of New South Wales  
ABN 85 132 812 143



## ANSWER



**These images show reticular pigmentary changes in the peripheral fundus of both eyes which are hypo-autofluorescent as might be expected in a female carrier of choroideraemia.**

**Due to the sensitive nature of the diagnosis, the patient was not immediately given a diagnosis but was referred to an ophthalmologist for confirmation first and referral for appropriate counselling services.**

**Centre for Eye Health**

The University of New South Wales  
Rupert Myers Building (south wing), Barker St, Gate 14  
Kensington NSW 2052

T. (02) 8115 0700 / 1300 421 960 F. (02) 8115 0799 E. [enquiries@cfeh.com.au](mailto:enquiries@cfeh.com.au)  
[cfeh.com.au](http://cfeh.com.au)

An initiative of Guide Dogs NSW/ACT and The University of New South Wales  
ABN 85 132 812 143