



**CFEH**

**facebook**



**Cases**

Centre for Eye Health

## CFEH Facebook Case #4

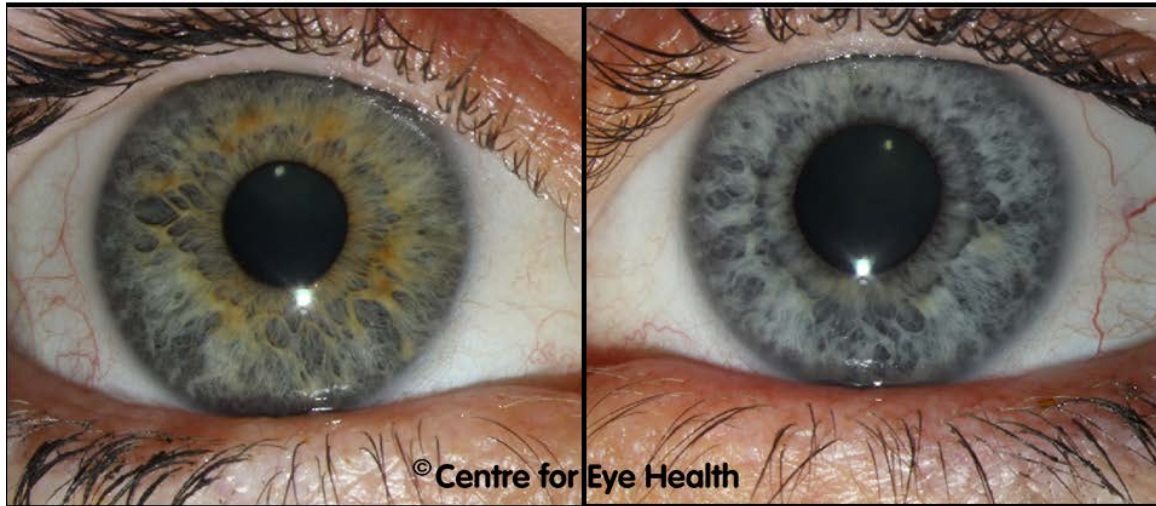A 42 year old female has noticed a floater in her left eye for many years but no flashes. She also reports "hazy" vision in this eye that has been present all her life. She suffers from allergies but reports no history of pain or inflammation in the eyes. The anterior chamber is clear.

Best corrected visual acuity was 6/3.8 OD and 6/6 OS

IOP measured with Goldmann tonometry was 12mmHg OD and 14mmHg OS

Corneal thickness was 514 $\mu$ m OD and 513 $\mu$ m OS

Anterior images are shown below. What is the diagnosis and what complications must you look out for?



### Centre for Eye Health

The University of New South Wales  
Rupert Myers Building (south wing), Barker St, Gate 14  
Kensington NSW 2052

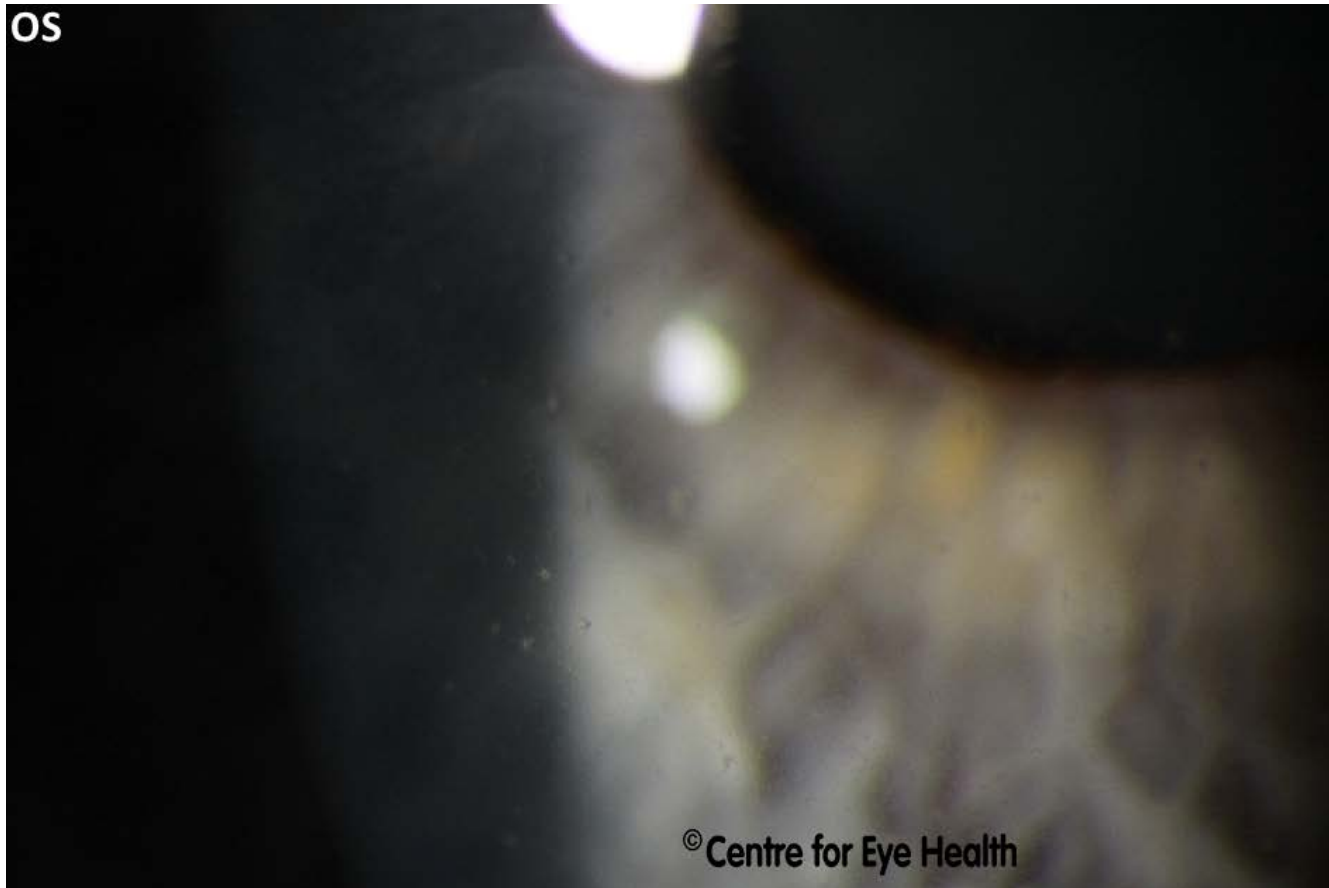
T. (02) 8115 0700 / 1300 421 960 F. (02) 8115 0799 E. [enquiries@cfeh.com.au](mailto:enquiries@cfeh.com.au) [cfeh.com.au](http://cfeh.com.au)

An initiative of Guide Dogs NSW/ACT and The University of New South Wales

ABN 85 132 812 143



Centre for Eye Health



**Centre for Eye Health**

The University of New South Wales  
Rupert Myers Building (south wing), Barker St, Gate 14  
Kensington NSW 2052

**T.** (02) 8115 0700 / 1300 421 960 **F.** (02) 8115 0799 **E.** [enquiries@cfeh.com.au](mailto:enquiries@cfeh.com.au) [cfeh.com.au](http://cfeh.com.au)

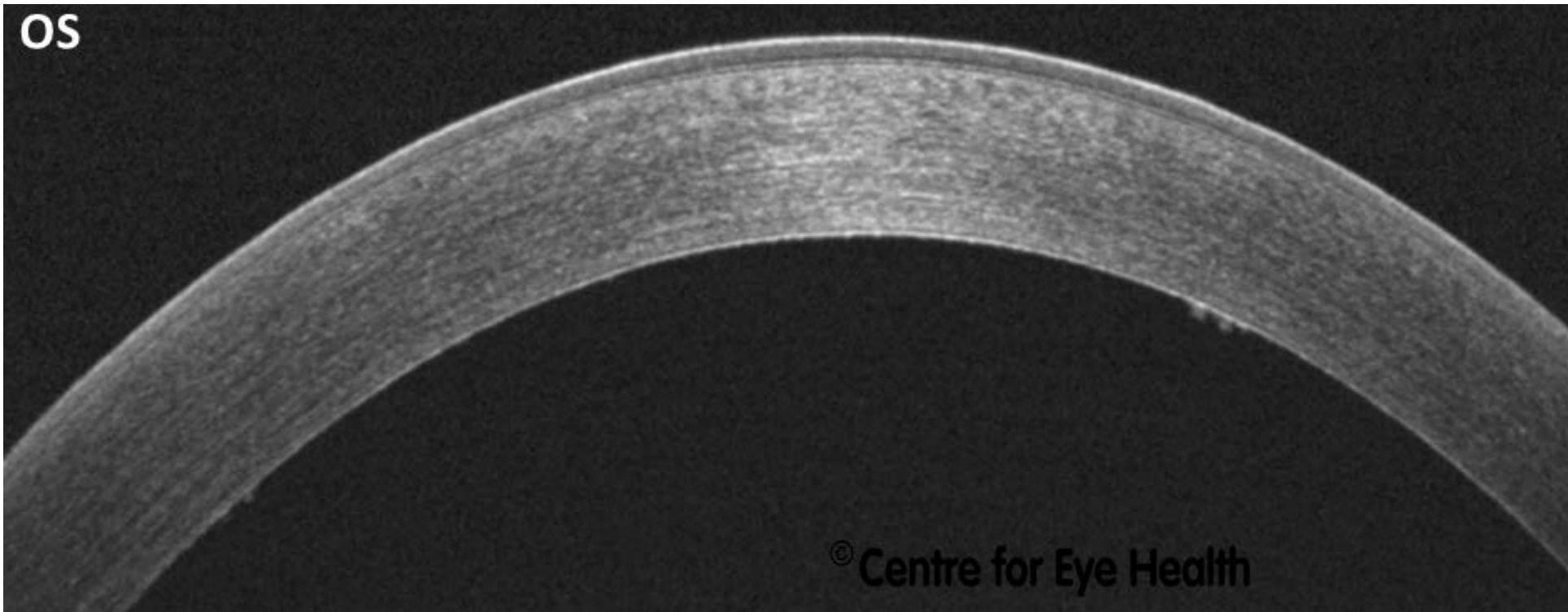
*An initiative of Guide Dogs NSW/ACT and The University of New South Wales*

ABN 85 132 812 143



Centre for Eye Health

OS



**Centre for Eye Health**

The University of New South Wales

Rupert Myers Building (south wing), Barker St, Gate 14

Kensington NSW 2052

T. (02) 8115 0700 / 1300 421 960 F. (02) 8115 0799 E. [enquiries@cfeh.com.au](mailto:enquiries@cfeh.com.au) [cfeh.com.au](http://cfeh.com.au)

An initiative of Guide Dogs NSW/ACT and The University of New South Wales

ABN 85 132 812 143



# ANSWER

## Fuchs Uveitis Syndrome (Previously known as Fuchs Heterochromic Iridocyclitis)

**Fuchs uveitis syndrome (FUS) is a chronic, mild non-granulomatous anterior uveitis. It has been estimated that 90% of cases are unilateral and patients can be either symptomatic or asymptomatic.**

**There are a wide variety of possible presentations, however the classic signs are as follows:**

- 1. Hypochromia of the affected eye (iris heterochromia) – in this case the affected eye is the left eye which has notably less pigment than the right eye. It is important to note that this may not be obvious in patients with dark irises.**
- 2. Fine keratic precipitates on the corneal endothelium – typically stellate or dendritic in appearance. These KP's can be seen in the anterior photo given, and from the OCT we can see confirm that they are located on the endothelium. It should be noted that while mutton-fat KP's may occasionally appear in FUS, they are more typically found in granulomatous uveitis or Posner-Schlossman Syndrome.**
- 3. Mild or low-grade iridocyclitis – this patient shows no signs of active inflammation at this time and reports no inflammatory symptoms in the past. The mild nature of the iridocyclitis can cause a patient to be asymptomatic as in this case.**
- 4. Iris atrophy – develops over time and is not yet obvious in this case although some of the inferior and temporal iris crypts may be slightly enlarged, potentially indicating some early atrophy. As mentioned above, these changes may not be immediately obvious in patients with dark irises, which typically manifest as a “beaten metal” appearance.**

**Other characteristic features can include iris nodules (Koepple nodules on the pupillary margin and Busacca nodules on the iris surface); prominent iris blood vessels (due to gradual iris atrophy); iris crystals (Russell bodies) and mild vitritis. Synechiae and macular oedema are not present in FUS. Importantly, IOP of the affected eye can also be elevated during an episode of iritis.**

# ANSWER

Possible complications include:

1. **Sub-capsular cataract – caused by severe anterior inflammation (anterior sub-capsular opacity) or vitritis (cortical and posterior sub-capsular opacities)**
2. **IOP elevation and secondary open angle glaucoma (SOAG) due to damaged aqueous outflow caused by recurrent episodes of uveitis. In some cases, patients may experience symptoms of increased IOP (such as haloes around lights), in isolation or in conjunction with inflammatory symptoms.**

**In the acute inflammatory phase of FUS, the initiation of treatment is controversial: while it is typically an asymptomatic and self-limiting condition, some patients may complain of significant symptoms of pain and photophobia as expected in uveitis.**

**In such cases, a titrated dose of topical steroid can be initiated (e.g. prednisolone acetate 1% qid). In addition to the treatment of uveitis, it is thought that the acute increase in IOP is due to inflammation of the trabecular meshwork (trabeculitis), which impairs aqueous outflow. Hence, the use of corticosteroid is thought to be another method of addressing acutely raised IOP.**

**Treatment of SOAG usually involves aqueous suppressants ( $\beta$ -blockers,  $\alpha$ -agonists and / or carbonic anhydrase inhibitors). The use of prostaglandin analogs is controversial as it is thought they may exacerbate the inflammatory response or cause recurrent uveitis, and laser treatment may be contra-indicated in FUS.**

**For more detailed information on this condition and its atypical variants, please refer to the article published by CFEH's Jack Phu et al. "Atypical Features of Fuchs Uveitis Syndrome" Optometry and Vision Science (2015) Vol 92 no 11 pp394-403. Please email Jack if you would like a copy [j.phu@cfeh.com.au](mailto:j.phu@cfeh.com.au)**