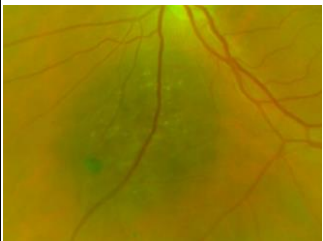
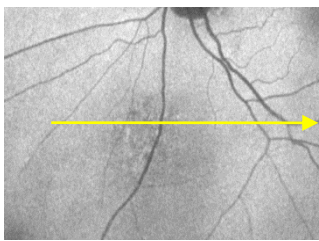
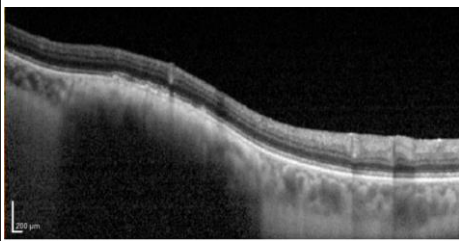
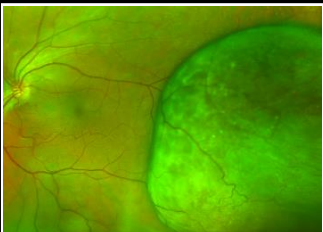
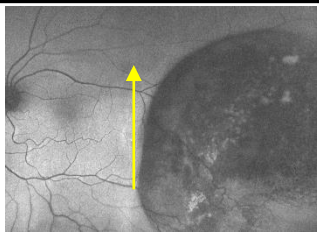
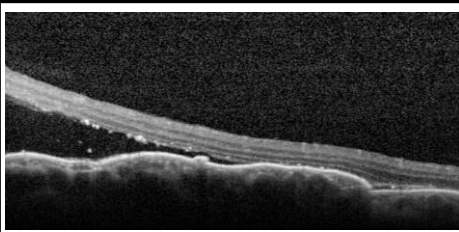

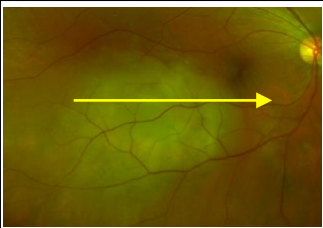
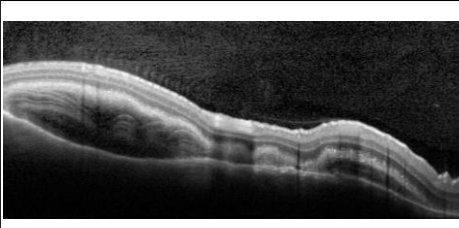




PIGMENTED LESIONS OF THE POSTERIOR EYE

©CFEH

Optomap/retinal photo	Fundus Autofluorescence (FAF)	Optical coherence tomography (OCT)	Description
Choroidal Naevus			
			<ul style="list-style-type: none"> • Common, benign lesion with detectable borders, round/oval in shape. • Typically located posterior to the equator. • Chronic naevi may show atrophy, hyperplasia, fibrous/osseous metaplasia and overlying drusen, RPE detachment and/or an RPE trough. • Less than 2mm thick and less than 5mm in diameter. • Carries up to a 1% lifetime risk of malignant transformation. <p><i>Documentation and routine review required.</i></p>
Choroidal Melanoma			
			<ul style="list-style-type: none"> • Most common primary malignant intraocular neoplasm in adults. • Solitary mass that is acoustically hollow on ultrasound. • Greater than 2mm thick. • May be associated with lipofuscin (overlying orange pigment), sub-retinal fluid or haemorrhage, sentinel vessels, choroidal folds, retinal detachment or inflammation. <p><i>Prompt referral to an Ophthalmologist is required.</i></p>
Choroidal Hemangioma			
 Image Courtesy of Dr N.Assaad	FAF not available	OCT not available	<ul style="list-style-type: none"> • Benign vascular tumours that are characterised by collections of vessels within the choroid of various sizes. • Localised lesions are red-orange, round/oval, and located in the posterior choroid. • Diffuse lesions appear as a marked thickening of the choroid and are associated with Sturge-Weber syndrome. • May be associated with sub-retinal fluid (SRF) or chronic macular oedema. <p><i>Documentation and routine review with referral of SRF or macular oedema</i></p>
Choroidal Metastasis			
	FAF not available		<ul style="list-style-type: none"> • Ill-defined, yellow lesions • Often associated with overlying pigmentary changes. • Multifocal and/or bilateral in 25% of cases. • Mildly elevated (less than 3mm). • May be symptomatic due to an associated exudative retinal detachment. • Primary lesion elsewhere in the body (commonly lungs or breast). <p><i>Prompt referral to an Ophthalmologist is required.</i></p>



PIGMENTED LESIONS OF THE POSTERIOR EYE

©CFEH

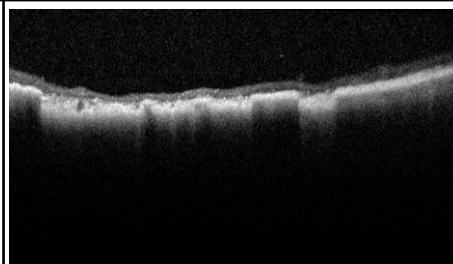
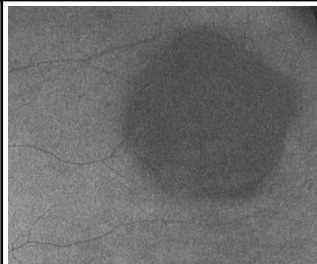
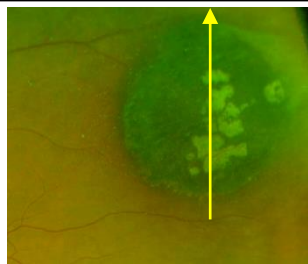
Optomap /retinal photo

Fundus Autofluorescence (FAF)

Optical coherence tomography (OCT)

Description

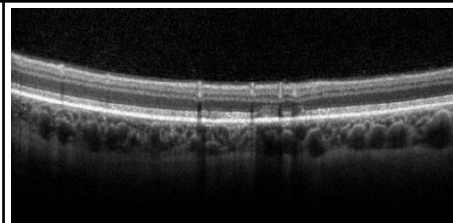
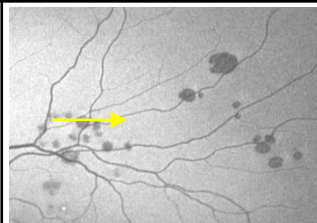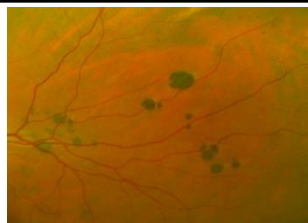
Congenital hypertrophy of the RPE (CHRPE)



- Benign lesion, typically unilateral and asymptomatic.
- Round, flat and heavily pigmented with slow progressive enlargement.
- Often have atrophied window-like defects (lacunae) and/or a marginal halo with overlying vessel sheathing and attenuation.
- Associated with a relative scotoma in youth and absolute scotoma in adulthood.
- Rarely can develop into an RPE adenoma (benign epithelioma) or adeno-carcinoma (malignant epithelioma), suggested by a nodular appearance, exudation or unusual vascularisation.

Documentation and routine review required.

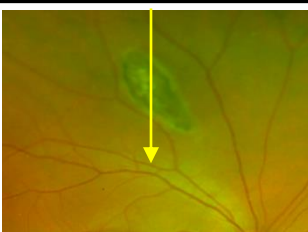Congenital Grouped Pigmentation of the RPE ("Bear Tracks")



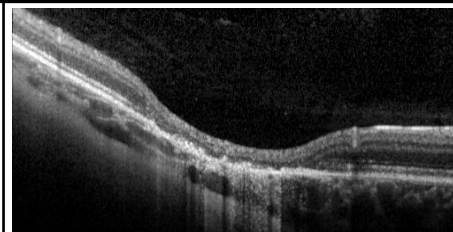
- Multiple small, flat, black lesions clustered in a single quadrant.
- Lesions commonly increase in size toward the periphery.
- FAF shows the lesions to be typically hypo-autofluorescent.
- OCT imaging often shows no obvious abnormalities.

Documentation and routine review required.

Pigmented Ocular Fundus Lesions (POFL) of Familial Adenomatous Polyposis (FAP)



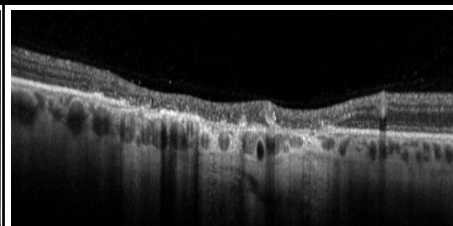
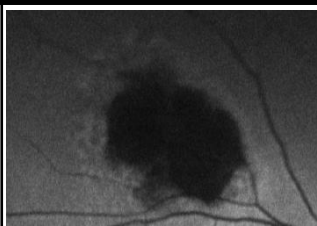
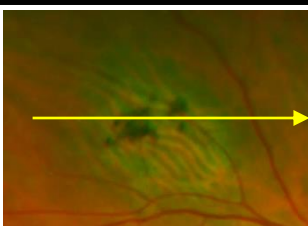
FAF not available



- Pisciform shaped lesions often surrounded by a hypo-pigmented halo
- Usually benign and asymptomatic but can cause visual field scotomas if large.
- Bilateral and multiple in presentation, commonly found around the equator.
- Multiple and larger lesions are associated with FAP, a condition that untreated leads to malignant carcinoma of the colon which is usually fatal.

Prompt referral to an Ophthalmologist is required.

Reactive Hyperplasia of the RPE



- Irregularly shaped, minimally elevated, well demarcated areas of pigment clumping.
- Minimal change over time.
- May be idiopathic or secondary to intraocular inflammation, trauma, haemorrhage or retinal detachment.

Documentation and routine review required. Management of the underlying cause.



PIGMENTED LESIONS OF THE POSTERIOR EYE

©CFEH

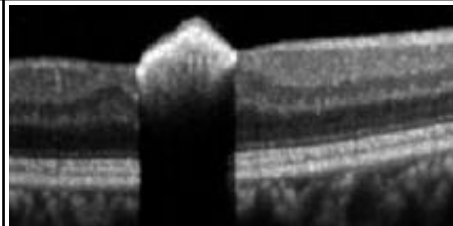
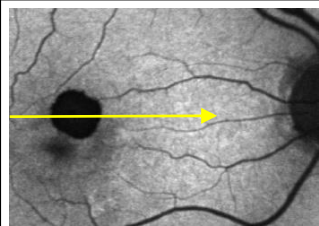
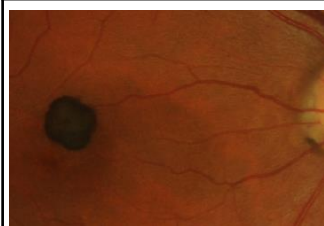Optomap/retinal photo

Fundus Autofluorescence (FAF)

Optical coherence tomography (OCT)

Description

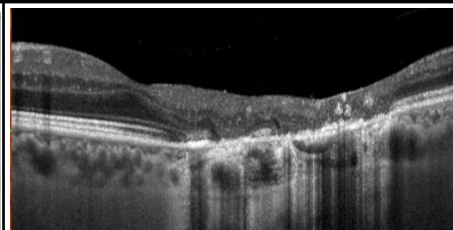
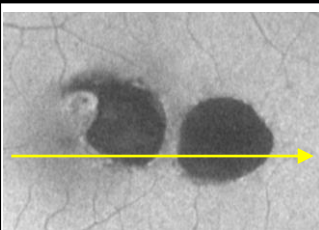
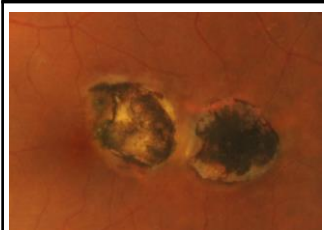
Congenital Simple Hamartoma of the RPE (Congenital Hyperplasia of the RPE, CSRPEH)



- Small, nodular, darkly pigmented, typically benign lesion within the macula.
- May be associated with feeder vessels or overlying traction.
- OCT shows a well demarcated, highly reflective, slightly elevated lesion with posterior shadowing.
- FAF shows a uniform hypo-autofluorescent lesion.

Documentation and routine review required

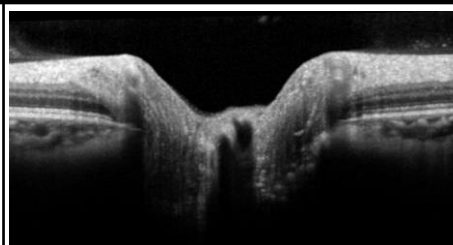
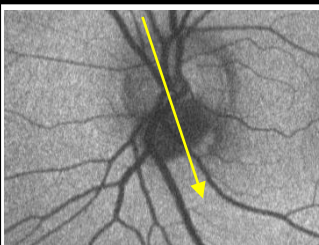
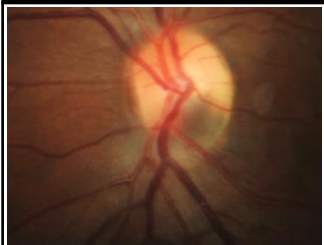Chorioretinal scarring associated with toxoplasmosis



- Inactive toxoplasmosis lesions appear as atrophic chorio-retinal scarring surrounded by a pigmented border.

Documentation and routine review required

Melanocytoma of the optic nerve, Retina and Choroid



- Unilateral, small (<2mm diameter, <1mm thick) lesions involving the optic nerve and adjacent choroid/retina.
- Choroidal component resembles a choroidal naevus
- Retinal component is typically black with feathery margins.
- Associated with optic nerve head oedema, retinal oedema, retinal haemorrhages, retinal exudates and/or subretinal fluid.
- 1-2% of cases progress to malignancy.

Documentation and routine review required

This chair-side reference was designed to assist optometrists in private practice when distinguishing between pigmented lesions of the fundus. It provides general information only and may not be applicable to atypical cases. A systematic approach to lesion assessment involving careful consideration of a lesion's characteristics (such as location, size, shape, colouration, thickness and associated signs such as drusen or subretinal fluid) may be helpful when forming a diagnosis. Additionally, a useful mnemonic was developed by Carol and Jerry Shields that describes the risk factors for neoplasm growth (ocular melanoma):

To Find Small Ocular Melanoma Using Helpful Hints Daily¹

- | | | | |
|--------------------|-------------------------------|------------------------------------|-------------------------------|
| ▪ Thickness > 2mm | ▪ Symptoms | ▪ Margins within 3mm of optic disc | ▪ Absence of depigmented Halo |
| ▪ Subretinal Fluid | ▪ Orange pigment (lipofuscin) | ▪ Ultrasound intrinsically hollow | ▪ Absence of overlying Drusen |

¹ Shields CL et al. Choroidal Nevus Transformation into Melanoma. Arch Ophthalmol. 2009; 127(8): p981-987.