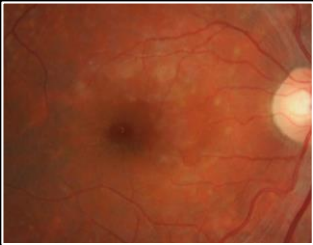
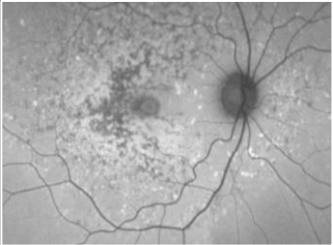
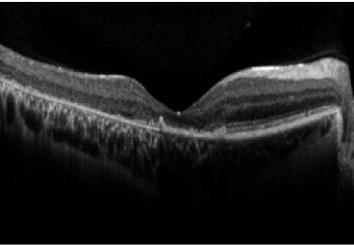
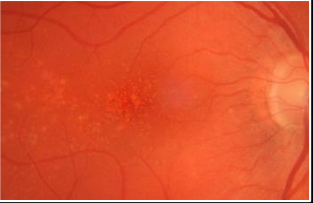
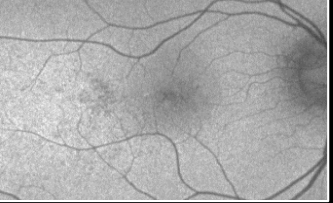
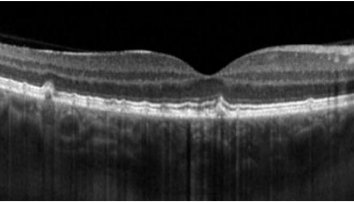


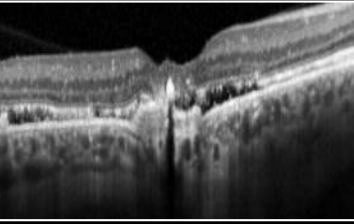




CHAIR-SIDE REFERENCE: MACULA DYSTROPHIES

Macula dystrophies are a **heterogeneous** group of inherited disorders, typically presenting with **bilateral**, relatively **symmetrical** macular abnormalities that can lead to **progressive central vision loss**.

MACULA DYSTROPHIES			
Retinal Photo	Fundus Autofluorescence	OCT	Description
ABCA4-associated retinopathy or Stargardt disease			<ul style="list-style-type: none"> • Age of onset: Most commonly childhood, adult-onset phenotypes also reported. • Inheritance Pattern: Predominantly autosomal recessive. • Fundus appearance: Variable. Retinal flecks, predominantly located around the macula with variable midperipheral distribution and associated with macular atrophy. • OCT: Flecks appear as focal RPE thickening which can progress to outer retinal layer atrophy. Macular features may include: subfoveal photoreceptor attenuation or disruption, and hyperreflective external limiting membrane. • FAF: May have decreased FAF centrally and hyper-FAF pattern of flecks. • Visual prognosis: Gradual and progressive visual decline ranging from 6/15-6/60. Early onset is associated with more severe visual impairment.
			
Autosomal dominant drusen/ Malattia Leventinese/ Doyme honeycomb retinal dystrophy			
			<ul style="list-style-type: none"> • Age of onset: 3rd to 4th decade of life. • Inheritance Pattern: Autosomal dominant inheritance pattern with full penetrance. • Fundus appearance: Drusen-like deposits at the macula, which may radiate from the fovea or show honeycomb-like appearance. • OCT: Hyper-reflective thickening of the RPE-Bruch's membrane complex, disrupted photoreceptor integrity. • FAF: Typically show hyper-FAF in large drusen, but not in small radial drusen. • Visual prognosis: Highly variable. Some patients maintain useful reading vision until later in life. Vision loss usually is slow and secondary to macular atrophy or rarely, CNV.
Best Vitelliform Macular Dystrophy			
			


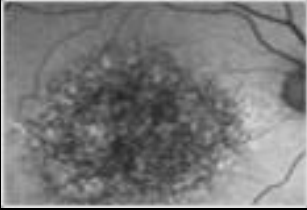
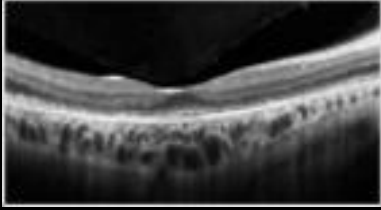
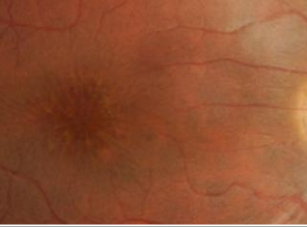
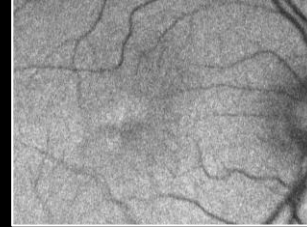
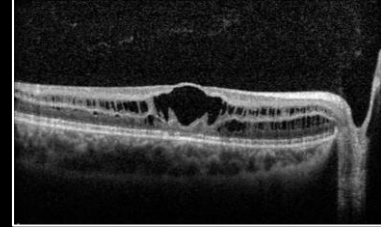
**The specific diagnosis of dystrophies may be uncertain in the absence of electrophysiology results and genetic testing .*

This reference is based on the current literature and evidence at the time of writing. This reference is designed a guide to aid diagnosis and management decisions however individual cases must be assessed in the context of all available clinical data.



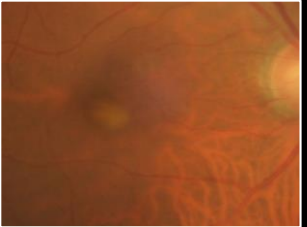
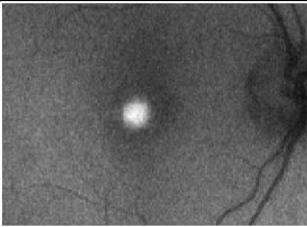
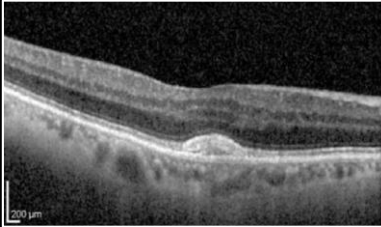
CHAIR-SIDE REFERENCE: MACULA DYSTROPHIES

Centre for Eye Health

Retinal Photo	Fundus Autofluorescence	OCT	Description
Central Areolar Choroidal Dystrophy   			<ul style="list-style-type: none"> • Age of onset: Presenting late childhood or early adulthood. • Inheritance Pattern: Autosomal dominant inheritance. • Fundus appearance: Initial parafoveal pigmentary RPE changes which progress to well defined areas of geographic atrophy involving RPE and choriocapillaris in the absence of flecks or drusen. • OCT: Partial loss of the outer nuclear layer with atrophy of the photoreceptor layer and the RPE–Bruch's membrane complex. • FAF: speckled FAF with areas of well-demarcated hypo-FAF pattern corresponding to atrophy. • Visual prognosis: bilateral decline in vision during the 4th and 5th decades of life. VA of 6/30-6/60 may be retained during the 7th-8th decades.
X-Linked Retinoschisis (XLRS)   			<ul style="list-style-type: none"> • Age of onset: Most common juvenile-onset retinal degeneration in male adolescents. Onset 1st-2nd decade of life. • Inheritance Pattern: X-linked recessive inheritance. • Fundus appearance: 'Spoke- wheel' folds of the macula (macular schisis) are the hallmark feature of XLRS. Around 50% also have peripheral retinal degenerations. • OCT: Splitting of the inner and outer retinal layers. • FAF: Central decreased signal over the macula and a rim of increased signal. May present an absent signal in a 'spoke wheel' pattern over the central fovea. • Visual prognosis: Prognosis is variable but can be relatively good in childhood if not complicated by retinal detachment or vitreous haemorrhage. Older adults may experience slow VA loss due to the development of macular atrophy.

PATTERN DYSTROPHIES

The following are all pattern dystrophy (PD) subtypes. They all have a variable age of onset (from 2nd-5th decade), with patients tending to remain asymptomatic until the 5th decade of life. The inheritance pattern is uncertain. While some studies suggest autosomal dominant patterns, recessive patterns have also been found. The course of PDs is relatively benign, although severe vision loss occurs in up to 50% of the affected individuals after the age of 70.

Adult-Onset Foveomacular Vitelliform Dystrophy   			<ul style="list-style-type: none"> • Fundus appearance: Bilateral subfoveal yellowish subretinal deposit at an average size of 1/3 disc diameter which can be associated with a central pigmented spot. Multifocal vitelliform lesions can be present in some cases. • OCT: Stage-dependent. <u>Vitelliform stage</u>: dome-shaped, homogenous, hyper-reflective subretinal lesion. <u>Pseudohypopyon stage</u>: a hypo-reflective area corresponding to partial liquefaction of the lesion. <u>Vitelliruptive stage</u>: lesion flattens, much of the fluid is absorbed, some loss of photoreceptors. <u>Atrophic stage</u>: atrophy of the outer retina and RPE is evident. • FAF: Hyper-FAF signal corresponding to vitelliform material, hypo-FAF corresponding to atrophy (if present)
---	--	--	---



CHAIR-SIDE REFERENCE: MACULA DYSTROPHIES

Retinal Photo	Fundus Autofluorescence	OCT	Description
Multifocal Pattern Dystrophy simulating Stargardt			<ul style="list-style-type: none"> • Fundus appearance: Irregular yellow flecks within the posterior pole that resemble flecks in Stargardt disease. It may be differentiated from Stargardt disease by relatively late age of onset, comparably good visual acuity and no display of dark choroid on fluorescein angiography. • OCT: Disturbance and abnormality in the photoreceptor outer segment-RPE level • FAF: Characteristic hyper-autofluorescent pattern on FAF at the initial stages with small adjacent zone of hypo-FAF.
Butterfly Pattern Dystrophy			
			<ul style="list-style-type: none"> • Fundus appearance: Yellow-white deposits consisting of 3-5 linear spokes, resembling the wings of a butterfly. Dark coloured lesions have also been identified. • OCT: The yellow lesions show hyper-reflective changes at the photoreceptor-RPE interface. • FAF: Characteristic hyper-autofluorescent pattern on FAF
Reticular Dystrophy of the RPE			
Fundus Pulverulentus			<ul style="list-style-type: none"> • Fundus appearance: RPE stippling at the macula occurs with fine pigment clumping interspersed with areas of RPE depigmentation, a characteristic 'punctiform' appearance. • OCT: Hyper-reflective lesions at RPE level corresponding to pigment clumping. • FAF: Mottled hyper-FAF and hypo-FAF pattern.