

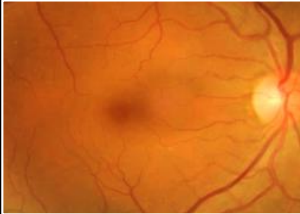
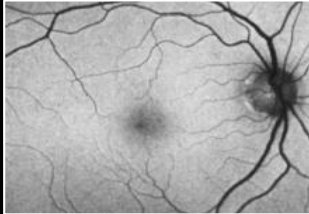
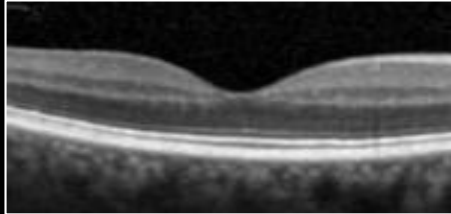
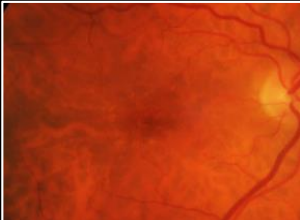
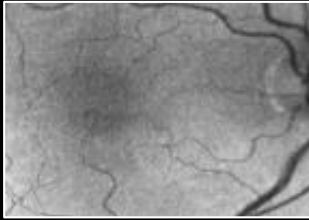
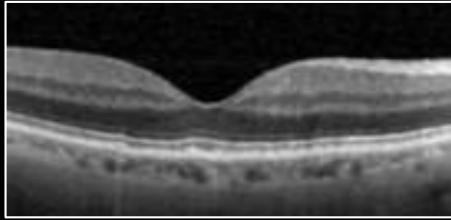


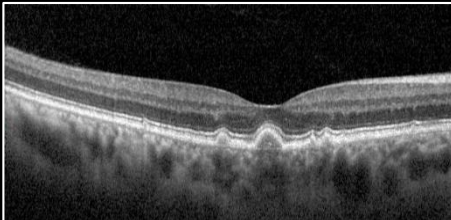


# CHAIR-SIDE REFERENCE: AGE-RELATED MACULAR DEGENERATION

## AGE-RELATED MACULAR DEGENERATION (AMD)

- This chair-side reference was designed to assist practising optometrists in distinguishing between the different stages and phenotypes of AMD. Current clinical guidelines stipulate that essential components of the clinical examination for the diagnosis of AMD includes a targeted case history, high-contrast visual acuity, refraction, stereoscopic slit lamp examination of the macula, dilated fundus examination of. It is also recommended to supplement clinical examination with available ocular imaging. Please note, this document provides general information only and may not be applicable to atypical cases.
- For further information, readers are encouraged to review the full texts:
  - Ferris et al. Clinical Classification of Age-related Macular Degeneration. *Ophthalmology* 2013;120:844–851
  - Sadda et al. Consensus Definition for Atrophy Associated with Age-Related Macular Degeneration on OCT Classification of Atrophy Report 3. *Ophthalmology* 2018;125:537-548
  - Agrón E, et al. for the AREDS and AREDS2 Research Groups, An Updated Simplified Severity Scale for Age-Related Macular Degeneration, Incorporating Reticular Pseudodrusen: Age-Related Eye Disease Study Report No. 42, *Ophthalmology* (2024)

## GRADING AMD

Retinal Photo	Fundus autofluorescence	Optical coherence tomography	Description
<b>Normal Aging Changes</b> 			<ul style="list-style-type: none"> <li>Drupelets only (&lt;63µm diameter, up to approximately half the width of a major branch retinal vein crossing the optic disc margin).</li> <li>Should not show any pigmentary abnormalities or other characteristics of early, intermediate or late AMD.</li> <li><b>FAF:</b> May appear near normal or display punctate spots of hyper- or hypo-autofluorescence.</li> <li><b>OCT:</b> Shows discrete irregularities or elevations of the RPE or may be too small to resolve.</li> </ul>
<b>Early AMD</b> 			<ul style="list-style-type: none"> <li>Medium drusen only (63 to 125µm diameter).</li> <li>Should not show any pigmentary abnormalities or other characteristics of intermediate or late AMD.</li> <li><b>FAF:</b> Appearance is similar to drupelets, medium drusen may display a variable normal, hyper- or hypo-fluorescence pattern.</li> <li><b>OCT:</b> Drusen typically appear as nodular elevations of the RPE/Bruch's membrane complex with medium internal reflectivity.</li> </ul>
<b>Intermediate AMD</b> 			<ul style="list-style-type: none"> <li>Large drusen (&gt;125µm in diameter) and/or hyper/hypo-pigmentary abnormalities associated with at least medium drusen.</li> <li>No characteristics of late AMD.</li> <li><b>FAF:</b> May feature a range of patterns, depending on the nature of the drusenoid deposits, including: normal, minimal change, focal increased, patchy, linear, lacelike, reticular, speckled, focal confluent, focal plaque-like or scattered.</li> <li><b>OCT:</b> Shows dome shaped, occasionally confluent, elevations of the RPE, with visible underlying BM. Hyper-pigmentary abnormalities may appear as discrete hyper-reflective foci with posterior shadowing.</li> </ul>



# CHAIR-SIDE REFERENCE: AGE-RELATED MACULAR DEGENERATION

## GRADING AMD (Cont.)

Retinal Photo	Fundus autofluorescence	Optical coherence tomography	Description
<b>Late AMD (Geographic Atrophy, Complete RPE and Outer Retinal Atrophy)</b>			<ul style="list-style-type: none"> <li>Sharply delineated, round or oval hypo-pigmented areas featuring increased visibility of underlying choroidal vessels.</li> <li>May be uni- or multi-lobular, with/without foveal involvement. Coalesce over time to form a ring, eventually involving the fovea centralis.</li> <li>Also displays signs of other AMD stages.</li> <li><b>FAF:</b> Easier to visualise using FAF, appearing as single or multiple areas of well-demarcated, marked hypo-auto fluorescence.</li> <li><b>OCT:</b> Shows corresponding zones of RPE disruption or attenuation, homogenous hyper-transmission into the choroid (&gt; or equal 250 microns) and overlying photoreceptor degeneration.</li> </ul>
<b>Late AMD (Neovascular AMD) – Active Lesion</b>			
			<ul style="list-style-type: none"> <li>May feature any of: RPE or retinal detachment, intraretinal, subretinal or sub-RPE fluid, scarring, glial tissue or fibrin like deposits, subretinal haemorrhage and/or hard exudates.</li> <li>Neovascular lesions may appear subtle, green-grey or pink-yellow often complicated by the secondary signs above.</li> <li><b>FAF:</b> Hyper-AF may be present in the areas of SRF, and hypo-AF in the presence of haemorrhage, exudate and fibrovascular membranes. Can also present with normal or near normal FAF.</li> <li><b>OCT:</b> PEDs present as broad elevations of the RPE band anterior to BM with hypo- or mixed internal reflectivity with or without serous exudation.</li> </ul>
<b>Late AMD (Neovascular AMD) – Disciform Scar</b>			
			<ul style="list-style-type: none"> <li>Fundus photography may show haemorrhages and/or exudates as well as disciform scarring. This scarring represents regression of the vascular component and an increase in the fibrous component.</li> <li><b>FAF:</b> Consistently demonstrates uneven hypo-AF of the lesion, surrounded by marked hyper-AF.</li> <li><b>OCT:</b> Will typically show a large, well-demarcated, highly hyper-reflective lesion associated with loss and dysplasia of the overlying retinal layers. Sub-retinal hyper-reflective material (SHRM) may be noted.</li> </ul>

Abbreviations: AMD, Age-related macular degeneration; OCT, Optical coherence tomography; FAF, Fundus autofluorescence; RPE, Retinal pigment epithelium; BM, Bruch's membrane; ISe, Inner segment ellipsoid; ELM, External limiting membrane; ONL, Outer nuclear layer; HFL, Henle's fibre layer; GA, Geographic atrophy; FA, Fluorescein angiography; PED, Pigment epithelium detachment



**CFEH TELEHEALTH**  
SUPPORTING OPTOMETRISTS

WWW.CENTREFOREYEHEALTH.COM.AU/TELEHEALTH

This reference is based on the current literature and evidence at the time of writing. This reference is designed a guide to aid diagnosis and management decisions however individual cases must be assessed in the context of all available clinical data.

For individual advice, Australian Optometrists can make a telehealth appointment with a senior CFEH staff optometrist. These consultations are at no charge, thanks to the support of Guide Dogs NSW/ACT.



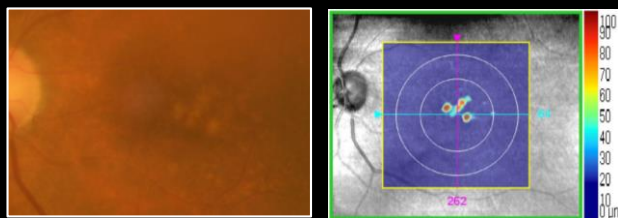
# CHAIR-SIDE REFERENCE: AGE-RELATED MACULAR DEGENERATION

## DISEASE PROGRESSION IN INTERMEDIATE AMD

The advent of OCT imaging allows clinicians to identify structural risk factors that may predict progression in intermediate AMD. These biomarkers may help in risk stratification and subsequently allow clinicians to offer tailored and individualized management plans. Below is an evidence-based summary of prognostic biomarkers that may predict a higher risk of progression from intermediate to late AMD, organised according to the strength of available evidence. Importantly, this field of research is highly active and rapidly evolving, particularly with the growing integration of artificial intelligence and machine learning.

### PROGNOSTIC BIOMARKERS WITH HIGH STRENGTH OF EVIDENCE

#### High Drusen Volume



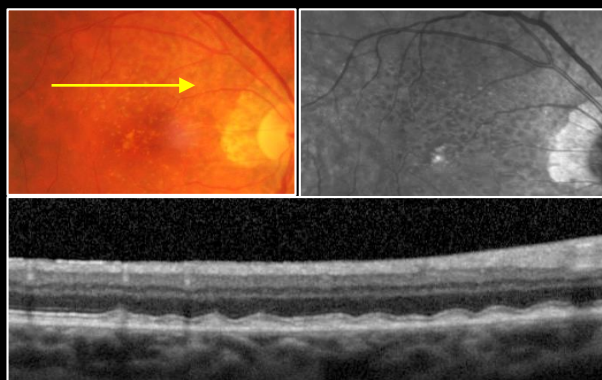
RPE Elevations	Current
Area in 3 mm Circle (mm <sup>2</sup> )	0.7
Area in 5 mm Circle (mm <sup>2</sup> )	0.7
Volume in 3 mm Circle (mm <sup>3</sup> )	0.04
Volume in 5 mm Circle (mm <sup>3</sup> )	0.04
Sub-RPE Illumination	Current
Area in 5 mm Circle (mm <sup>2</sup> )	0.0
Closest distance to Fovea (mm)	xxx

High drusen volume at the macula is the strongest risk factor for AMD progression. Drusen volume can be established qualitatively (a higher number of visible drusen at the macula confers a higher risk of progression) or quantitatively using some commercially available OCT software.

A drusen volume greater than or equal to 0.03mm<sup>3</sup> within a 3mm central circle is associated with a four-fold increase in progression risk from intermediate to late AMD when compared with drusen volume less than 0.03mm<sup>3</sup> (Abdelfattah et al. 2016).

Images show a retinal photograph and Cirrus *Advanced RPE Analysis* of a patient with high drusen volume.

#### Reticular Pseudodrusen



#### Updated AREDS Simplified Severity Scale (2024)

Score	AREDS SSS (no RPD)	AREDS SSS (with RPD)
0	~0.5%	3%
1	~4%	8%
2	12%	~30%
3	~25%	~60%
4	50%	~70%

Reticular pseudodrusen (RPD) are deposits in the sub-retinal space (above the RPE) and are distinct from conventional drusen which are located underneath the RPE. On FAF imaging, they present with an interlacing or reticular pattern. They can be associated with progression to both forms of late AMD.

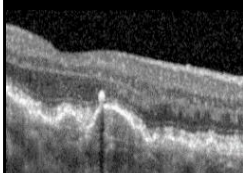
While there is still debate on the validity and utility of biomarkers and scales, the previously widely used AREDS Simplified Severity Scale was updated in 2024 to reflect the presence or absence of reticular pseudodrusen (table 1).

The AREDS Simplified Severity Scale estimates the risk of progression to late AMD within 5 years by assessing both eyes. The scoring system is as below:

- One point for each eye that has large drusen present
- One point for each eye that has pigmentary abnormalities at the macula
- If neither eye has large drusen, one point is still assigned if both eyes have medium-sized drusen.

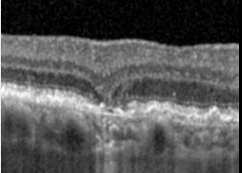
### POTENTIAL BIOMARKES THAT MAY INDICATE PROGRESSION OF INTERMEDIATE AMD

#### Hyper-reflective Foci



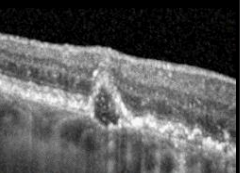
Discrete, well circumscribed, punctate lesion often overlying drusen

#### Nascent Geographic Atrophy



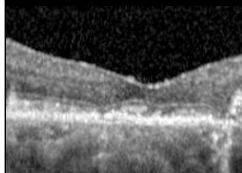
A hyporeflective, wedge-shaped band within the limits of the OPL and/or subsidence of the OPL and INL

#### Hypo-reflective Drusen Cores



Hypo-reflective or darker areas within drusen cores seen on OCT

#### Altered Integrity of Outer Retinal Hyper-reflective Bands



Interruptions in hyper-reflectivity, irregularity or attenuation of the ELM, EZ or IZ